

# skin<sup>med</sup><sup>®</sup>

## DERMATOLOGY FOR THE CLINICIAN

Indexed



Index Medicus/MEDLINE



Chinese Society of Dermatology



The Section on Dermatology  
College of Physicians of Philadelphia



The History of Dermatology Society



International Association of Ecological Dermatology (Eco-Derm)



Philippine Academy of Clinical and Cosmetic Dermatology



Lebanese Dermatological Society



Maltese Association of Dermatology and Venereology



Dermatology Insights and Inquiries



The International Academy of Cosmetic Dermatology



Association of Cutaneous Surgeons



Belarusian Society of Dermatovenerologists and Cosmetologists



North American Clinical Dermatology Society



The Dermatologic & Aesthetic Surgery International League



African Association for Dermatology

An Official Publication of

Published by: Pulse Marketing & Communications, LLC

January/February 2018 Volume 16 Issue 1

### EDITORIAL

**Fake News, Predatory Journals, Case Reports, Biostatistics, and Other Journalistic Musings—Part 1**  
*Heymann*

### COMMENTARY

**Media and the Skin**  
*Johanssen and Garrisi*

### ORIGINAL CONTRIBUTIONS

**Novel Drugs Implicated in Pigmented Purpuric Dermatoses**  
*Nwaneshiudu and Petronic-Rosic*

**Salivary Cortisol and Salivary Flow Rate in Clinical Types of Oral Lichen Planus**  
*Mansourian, Najafi, Nojumi, Parhami, and Moosavi*

**Retrospective Analysis of Pediatric Dermatologic Hospital Admissions**  
*Leczycka, Baranska-Rybak, Castellanos, and Nowicki*

### REVIEW

**Congenital Hypotrichosis and Congenital Atrichia**  
*Al-Dawsari and Kaliyadan*

**Self Assessment Examination**  
*Lambert*

### DEPARTMENTS

**NEW THERAPY UPDATE**  
**Odomzo® (Sonidegib)**  
*Gupta, Mays Abramovits, and Vincent*

**PERILS OF DERMATOPATHOLOGY**  
**Aggressive Mimicry in Dermatology: When a Basal or Squamous Cell Carcinoma Mimics a Spindle Cell Tumor**  
*John, Singh, Handler, and Lambert*

**THE HEYMANN FILE**  
**The Prescience of Bernie Ackerman: The Road from “Pseudoleukemia Cutis” to “Intralymphatic Proliferation of T-cell Lymphoid Blasts (IPTCLBs)”**  
*Heymann*

**PHOTO CAPSULE**  
**Gnathophyma**  
*Kumar and Das*

**NORTH AMERICAN CLINICAL DERMATOLOGIC SOCIETY**  
**Gauchos to Glaciers!: April 18–27, 2017, Argentina and the Galapagos Islands**  
*Berger*

**VIGNETTES OF DERMATOLOGIC HISTORY**  
**Ex-Lax®**  
*Bernhardt*

**CASE STUDIES**  
**Coccidioidomycosis**  
*Laffer and Ackerman*

**Tuberous Sclerosis Complex: A Classic Presentation**  
*Sehgal, Singh, Sharma, Rohatgi, Oberai, and Chatterjee*

**Pemphigus Vegetans Confined to the Face and Scalp**  
*Zaouak, Hammami, Salah, Debbeiche, and Fenniche*

**Disseminated Cutaneous Rhinosporidiosis**  
*Prabha, Arora, Chhabra, Joseph, Singh, Satpute, and Nagarkar*

**Woodworm Bites in a 52-Year-Old Man**  
*Conforti, Silvestre, and Dianzani*

**Multiple Grouped Scalp Nodules in a Middle-Aged Man: A Rare Case of Angiolymphoid Hyperplasia with Eosinophilia**  
*Husienzad, Friedman, Yang, Tran, and Lee*

**Glucose Monitoring Dermopathy**  
*Heymann*

**Bullous Diabeticorum: A Neglected Bullous Dermatoses**  
*Vangipuram, Hinojosa, Lewis, Downing, Hixson, Salas-Alanis, Tyring*



Scan this QR code with your QR reader

Otezla® (apremilast) is indicated for the treatment of patients with moderate to severe plaque psoriasis who are candidates for phototherapy or systemic therapy.

- ◆ Otezla was evaluated in 2 multicenter, double-blind, placebo-controlled trials of similar design. Patients with moderate to severe plaque psoriasis (N = 1257) were randomized 2:1 to Otezla 30 mg or placebo twice daily for 16 weeks, after a 5-day titration<sup>1,2</sup>
- ◆ Inclusion criteria: Age ≥18 years, BSA involvement ≥10%, sPGA ≥3, PASI score ≥12, candidates for phototherapy or systemic therapy<sup>1,3</sup>
- ◆ PASI-75 response at week 16 (primary endpoint)
  - ESTEEM 1: Otezla 33% vs placebo 5% (P < 0.0001)<sup>1,3</sup>
  - Similar PASI-75 response was achieved in ESTEEM 2<sup>1,2</sup>

BSA, body surface area; PASI, Psoriasis Area and Severity Index; sPGA, static Physician Global Assessment.

## INDICATIONS

Otezla® (apremilast) is indicated for the treatment of patients with moderate to severe plaque psoriasis who are candidates for phototherapy or systemic therapy.

Otezla is indicated for the treatment of adult patients with active psoriatic arthritis.

## IMPORTANT SAFETY INFORMATION

### Contraindications

- ◆ Otezla® (apremilast) is contraindicated in patients with a known hypersensitivity to apremilast or to any of the excipients in the formulation

### Warnings and Precautions

- ◆ Diarrhea, Nausea and Vomiting: Cases of severe diarrhea, nausea, and vomiting have been reported with the use of Otezla. Most events occurred within the first few weeks of treatment. In some cases patients were hospitalized. Patients 65 years of age or older and patients taking medications that can lead to volume depletion or hypotension may be at a higher risk of complications from severe diarrhea, nausea, or vomiting. Monitor patients who are more susceptible to complications of diarrhea or vomiting; advise patients to contact their healthcare provider. Consider Otezla dose reduction or suspension if patients develop severe diarrhea, nausea, or vomiting
- ◆ Depression: Treatment with Otezla is associated with an increase in depression. During clinical trials 1.3% (12/920) of patients reported depression, compared to 0.4% (2/506) on placebo. Suicidal behavior was observed in 0.1% (1/1308) of patients on Otezla, compared to 0.2% (1/506) on placebo. Carefully weigh the risks and benefits of treatment with Otezla for patients with a history of depression and/or suicidal thoughts/behavior, or in patients who develop such symptoms while on Otezla. Patients, caregivers, and families should be advised of the need to be alert for the emergence or worsening of depression, suicidal

thoughts or other mood changes, and they should contact their healthcare provider if such changes occur

- ◆ Weight Decrease: Body weight loss of 5-10% occurred in 12% (96/784) of patients treated with Otezla and in 5% (19/382) of patients treated with placebo. Monitor body weight regularly; evaluate unexplained or clinically significant weight loss, and consider discontinuation of Otezla
- ◆ Drug Interactions: Apremilast exposure was decreased when Otezla was co-administered with rifampin, a strong CYP450 enzyme inducer; loss of Otezla efficacy may occur. Concomitant use of Otezla with CYP450 enzyme inducers (e.g., rifampin, phenobarbital, carbamazepine, phenytoin) is not recommended

### Adverse Reactions

- ◆ Adverse reactions reported in ≥5% of patients were (Otezla%, placebo%): diarrhea (17, 6), nausea (17, 7), upper respiratory tract infection (9, 6), tension headache (8, 4), and headache (6, 4)

### Use in Specific Populations

- ◆ Pregnancy and Nursing Mothers: Otezla is Pregnancy Category C; it has not been studied in pregnant women. Use during pregnancy only if the potential benefit justifies the potential risk to the fetus. It is not known whether apremilast or its metabolites are present in human milk. Caution should be exercised when Otezla is administered to a nursing woman
- ◆ Renal Impairment: Otezla dosage should be reduced in patients with severe renal impairment (creatinine clearance less than 30 mL/min); for details, see Dosage and Administration, Section 2, in the Full Prescribing Information

### Please turn the page for Brief Summary of Full Prescribing Information.

References: 1. Otezla [package insert]. Summit, NJ: Celgene Corporation. 2. Data on file, Celgene Corporation. 3. Papp K, Reich K, Leonardi CL, et al. *J Am Acad Dermatol*. 2015;73(1):37-49. 4. Information derived from Symphony Health Solutions PrescriberSource PatientFocus data, Celgene proprietary methodology, April 2014 through June 2017.

\* Data includes healthcare professionals (dermatologists, rheumatologists, nurse practitioners, and physician assistants) and their Otezla prescriptions (including refills) from April 2014 through June 2017 for patients with plaque psoriasis or psoriatic arthritis. Source: Data on file, Celgene Corporation.

Get the latest news at [otezlapro.com](http://otezlapro.com)



Otezla® is a registered trademark of Celgene Corporation.  
© 2017 Celgene Corporation 07/17  
USII-APR170289



**Otezla**®  
(apremilast) 30mg tablets

**OTEZLA® (apremilast) tablets, for oral use**

The following is a Brief Summary; refer to Full Prescribing Information for complete product information.

**INDICATIONS AND USAGE**

OTEZLA® (apremilast) is indicated for the treatment of patients with moderate to severe plaque psoriasis who are candidates for phototherapy or systemic therapy.

**CONTRAINDICATIONS**

OTEZLA is contraindicated in patients with a known hypersensitivity to apremilast or to any of the excipients in the formulation [see Adverse Reactions (6.1)].

**WARNINGS AND PRECAUTIONS**

**Diarrhea, Nausea, and Vomiting:** There have been postmarketing reports of severe diarrhea, nausea, and vomiting associated with the use of OTEZLA. Most events occurred within the first few weeks of treatment. In some cases patients were hospitalized. Patients 65 years of age or older and patients taking medications that can lead to volume depletion or hypotension may be at a higher risk of complications from severe diarrhea, nausea, or vomiting. Monitor patients who are more susceptible to complications of diarrhea or vomiting. Patients who reduced dosage or discontinued OTEZLA generally improved quickly. Consider OTEZLA dose reduction or suspension if patients develop severe diarrhea, nausea, or vomiting.

**Depression:** Treatment with OTEZLA is associated with an increase in adverse reactions of depression. Before using OTEZLA in patients with a history of depression and/or suicidal thoughts or behavior prescribers should carefully weigh the risks and benefits of treatment with OTEZLA in such patients. Patients, their caregivers, and families should be advised of the need to be alert for the emergence or worsening of depression, suicidal thoughts or other mood changes, and if such changes occur to contact their healthcare provider. Prescribers should carefully evaluate the risks and benefits of continuing treatment with OTEZLA if such events occur. During the 0 to 16 week placebo-controlled period of the 3 controlled clinical trials, 1.3% (12/920) of patients treated with OTEZLA reported depression compared to 0.4% (2/506) treated with placebo. During the clinical trials, 0.1% (1/1308) of patients treated with OTEZLA discontinued treatment due to depression compared with none in placebo-treated patients (0/506). Depression was reported as serious in 0.1% (1/1308) of patients exposed to OTEZLA, compared to none in placebo-treated patients (0/506). Instances of suicidal behavior have been observed in 0.1% (1/1308) of patients while receiving OTEZLA, compared to 0.2% (1/506) in placebo-treated patients. In the clinical trials, one patient treated with OTEZLA attempted suicide while one who received placebo committed suicide.

**Weight Decrease:** During the controlled period of the trials in psoriasis, weight decrease between 5%-10% of body weight occurred in 12% (96/784) of patients treated with OTEZLA compared to 5% (19/382) treated with placebo. Weight decrease of  $\geq 10\%$  of body weight occurred in 2% (16/784) of patients treated with OTEZLA 30 mg twice daily compared to 1% (3/382) patients treated with placebo. Patients treated with OTEZLA should have their weight monitored regularly. If unexplained or clinically significant weight loss occurs, weight loss should be evaluated, and discontinuation of OTEZLA should be considered.

**Drug Interactions:** Co-administration of strong cytochrome P450 enzyme inducer, rifampin, resulted in a reduction of systemic exposure of apremilast, which may result in a loss of efficacy of OTEZLA. Therefore, the use of cytochrome P450 enzyme inducers (e.g., rifampin, phenobarbital, carbamazepine, phenytoin) with OTEZLA is not recommended [see Drug Interactions (7.1) and Clinical Pharmacology (12.3)].

**ADVERSE REACTIONS**

**Clinical Trials Experience in Psoriasis:** Because clinical trials are conducted under widely varying conditions, adverse reaction rates observed in the clinical trial of a drug cannot be directly compared to rates in the clinical trials of another drug and may not reflect the rates observed in clinical practice. Diarrhea, nausea, and upper respiratory tract infection were the most commonly reported adverse reactions. The most common adverse reactions leading to discontinuation for patients taking OTEZLA were nausea (1.6%), diarrhea (1.0%), and headache (0.8%). The proportion of patients with psoriasis who discontinued treatment due to any adverse reaction was 6.1% for patients treated with OTEZLA 30 mg twice daily and 4.1% for placebo-treated patients.

**Table 3: Adverse Reactions Reported in  $\geq 1\%$  of Patients on OTEZLA and With Greater Frequency Than in Patients on Placebo; up to Day 112 (Week 16)**

Preferred Term	Placebo (N=506) n (%)	OTEZLA 30 mg BID (N=920) n (%)
Diarrhea	32 (6)	160 (17)
Nausea	35 (7)	155 (17)
Upper respiratory tract infection	31 (6)	84 (9)
Tension headache	21 (4)	75 (8)
Headache	19 (4)	55 (6)
Abdominal pain*	11 (2)	39 (4)
Vomiting	8 (2)	35 (4)
Fatigue	9 (2)	29 (3)
Decrease appetite	5 (1)	26 (3)
Insomnia	4 (1)	21 (2)
Back pain	4 (1)	20 (2)
Migraine	5 (1)	19 (2)
Frequent bowel movements	1 (0)	17 (2)
Depression	2 (0)	12 (1)
Bronchitis	2 (0)	12 (1)
Tooth abscess	0 (0)	10 (1)
Folliculitis	0 (0)	9 (1)
Sinus headache	0 (0)	9 (1)

\*Two subjects treated with OTEZLA experienced serious adverse reaction of abdominal pain.

Severe worsening of psoriasis (rebound) occurred in 0.3% (4/1184) patients following discontinuation of treatment with OTEZLA (apremilast).

**DRUG INTERACTIONS**

**Strong CYP 450 Inducers:** Apremilast exposure is decreased when OTEZLA is co-administered with strong CYP450 inducers (such as rifampin) and may result in loss of efficacy [see Warnings and Precautions (5.3) and Clinical Pharmacology (12.3)].

**USE IN SPECIFIC POPULATIONS**

**Pregnancy:** Pregnancy Category C: OTEZLA should be used during pregnancy only if the potential benefit justifies the potential risk to the fetus. **Pregnancy Exposure Registry:** There is a pregnancy exposure registry that monitors pregnancy outcomes in women exposed to OTEZLA during pregnancy. Information about the registry can be obtained by calling 1-877-311-8972.

**Nursing Mothers:** It is not known whether OTEZLA or its metabolites are present in human milk. Because many drugs are present in human milk, caution should be exercised when OTEZLA is administered to a nursing woman. **Pediatric use:** The safety and effectiveness of OTEZLA in pediatric patients less than 18 years of age have not been established. **Geriatric use:** Of the 1257 patients who enrolled in two placebo-controlled psoriasis trials (PSOR 1 and PSOR 2), a total of 108 psoriasis patients were 65 years of age and older, including 9 patients who were 75 years of age and older. No overall differences were observed in the efficacy and safety in elderly patients  $\geq 65$  years of age and younger adult patients  $< 65$  years of age in the clinical trials. **Renal Impairment:** Apremilast pharmacokinetics were characterized in subjects with mild, moderate, and severe renal impairment as defined by a creatinine clearance of 60-89, 30-59, and less than 30 mL per minute, respectively, by the Cockcroft-Gault equation. While no dose adjustment is needed in patients with mild or moderate renal impairment, the dose of OTEZLA should be reduced to 30 mg once daily in patients with severe renal impairment [see Dosage and Administration (2.2) and Clinical Pharmacology (12.3)]. **Hepatic Impairment:** Apremilast pharmacokinetics were characterized in patients with moderate (Child Pugh B) and severe (Child Pugh C) hepatic impairment. No dose adjustment is necessary in these patients.

**OVERDOSAGE**

In case of overdose, patients should seek immediate medical help. Patients should be managed by symptomatic and supportive care should there be an overdose.

Manufactured for: Celgene Corporation, Summit, NJ 07901  
OTEZLA® is a registered trademark of Celgene Corporation.  
Pat. <http://www.celgene.com/therapies>  
©2014-2017 Celgene Corporation, All Rights Reserved.

**EDITORIAL**

**Fake News, Predatory Journals, Case Reports, Biostatistics, and Other Journalistic Musings—Part 1** ..... 8  
*Warren R. Heymann, MD*

**COMMENTARY**

**Media and the Skin** ..... 11  
*Jacob Johansen, PhD; Diana Garrisi, PhD*

**ORIGINAL CONTRIBUTIONS**

**Novel Drugs Implicated in Pigmented Purpuric Dermatoses** ..... 13  
*Adaobi I. Nwaneshiudu, MD, PhD; Vesna Petronic-Rosic, MD, MSc*

**Salivary Cortisol and Salivary Flow Rate in Clinical Types of Oral Lichen Planus** ..... 19  
*Arash Mansourian, DDS, MSc; Shamsoulmoulouk Najafi, DDS, MSc; Nazila Nojoumi, DDS; Parisa Parhami, DDS; Mahdieh-Sadat Moosavi, DDS, MSc*

**Retrospective Analysis of Pediatric Dermatologic Hospital Admissions** ..... 23  
*Martina Eva Leczycka, MD; Wioletta Baranska-Rybak, MD, PhD; Juliana Orrego Castellanos, BS; Roman Nowicki, MD, PhD*

**REVIEW**

**Congenital Hypotrichosis and Congenital Atrichia** ..... 27  
*Najla A. Al-Dawsari, MD; Feroze Kaliyadan, MD*

**Self Assessment Examination** ..... 33  
*W. Clark Lambert, MD, PhD*

**DEPARTMENTS**

**NEW THERAPY UPDATE**

*William Abramovits, MD; Aditya K. Gupta, MD, PhD, FRCPC, Section Editors*

**Odomzo® (Sonidegib)** ..... 35  
*Aditya K. Gupta, MD, PhD, FRCPC; Rachel R. Mays, BSc; William Abramovits, MD; Kimberly Dawn Vincent, MD*

**PERILS OF DERMATOPATHOLOGY**

*W. Clark Lambert, MD, PhD, Section Editor*

**Aggressive Mimicry in Dermatology: When a Basal or Squamous Cell Carcinoma Mimics a Spindle Cell Tumor** ..... 39  
*Ann M. John, BA; Parmvir Singh, BS; Marc Z. Handler, MD; W. Clark Lambert, MD, PhD*

**THE HEYMAN FILE**

*Warren R. Heymann, MD, Section Editor*

**The Prescience of Bernie Ackerman: The Road from “Pseudoleukemia Cutis” to “Intralymphatic Proliferation of T-cell Lymphoid Blasts (IPTCLBs)”** ..... 43  
*Warren R. Heymann, MD*

**PHOTO CAPSULE**

*Snejina Vassileva, MD, PhD, Section Editor*

**Gnathophyma** ..... 45  
*Piyush Kumar, MD; Anupam Das, MD*

**SOCIETY HIGHLIGHTS OF THE 58TH ANNUAL MEETING OF THE NORTH AMERICAN CLINICAL DERMATOLOGIC SOCIETY**

**Gauchos to Glaciers!: April 18–27, 2017, Argentina and the Galapagos Islands** ..... 47  
*Robert S. Berger, MD*

**VIGNETTES OF DERMATOLOGIC HISTORY**

*Mark Bernhardt, MD, Section Editor*

**Ex-Lax®** ..... 49  
*Mark Bernhardt, MD*

**CASE STUDIES**

*Vesna Petronic-Rosic, MD, MSc, Section Editor*

**Coccidioidomycosis** ..... 51  
*Matthew Laffer; Lindsay Ackerman, MD*

**Tuberous Sclerosis Complex: A Classic Presentation** ..... 55  
*Virendra N. Sehgal, MD, FNASc, FAMS, FRAS (Lond); Navjeeven Singh, MD; Sonal Sharma, MD; Jolly Rohatgi, MS; Rakesh Oberai, MD; Kingsbuk Chatterjee, DNB, MINAMs*

**Pemphigus Vegetans Confined to the Face and Scalp** ..... 60  
*Anissa Zaouak, MD; Houda Hammami, MD; Mariem Belhaj Salah, MD; Achraf Debbiche, MD; Samy Fenniche, MD*

**Disseminated Cutaneous Rhinosporidiosis** ..... 63  
*Neel Prabha, MBBS, MD; Ripudaman Arora, MBBS, MS; Namrata Chhabra, MBBS, MD; Williams Joseph, MS; Vandita Yogendra Singh, MBBS, MD; Satish Suresh Satpute, MBBS, MS; Nitin M. Nagarkar, MBBS, MS*

**Woodworm Bites in a 52-Year-Old Man** ..... 67  
*Claudio Conforti, MD; Maria Silvestre, MD; Caterina Dianzani, MD, PhD*

**Multiple Grouped Scalp Nodules in a Middle-Aged Man: A Rare Case of Angiolymphoid Hyperplasia with Eosinophilia** ..... 71  
*Lina Husienzad, BS; Ben Friedman, MD; Sherry X. Yang, MD; Amber Tran, MSN, CRNP; Jason B. Lee, MD*

**Glucose Monitoring Dermopathy** ..... 74  
*Warren R. Heymann, MD*

**Bullosis Diabeticorum: A Neglected Bullous Dermatitis** ..... 77  
*Ramya Vangipuram, MD; Tiffany Hinojosa, MD; Daniel J. Lewis, BA; Christopher Downing, MD; Caleb Hixson, DO; Julio César Salas-Alanis, MD, PhD; Stephen K. Tyring, MD, PhD*

**ABOUT OUR JOURNAL**

SKINmed: *Dermatology for the Clinician*®, print ISSN 1540-9740, online ISSN 1751-7125, is published bimonthly by Pulse Marketing & Communications, LLC, located at 4 Peninsula Avenue, Sea Bright, NJ 07760.

Printed in the USA.

Authors interested in submitting a paper should refer to the instructions located online at: <http://www.skinmedjournal.com/author-info.html>. Submissions should be e-mailed to the Editor at: [larryderm@yahoo.com](mailto:larryderm@yahoo.com)

Disclaimer: The Publisher, Editors, and Editorial Board cannot be held responsible for errors or any consequences arising from the use of information contained in this journal; the views and opinions expressed herein do not necessarily reflect those of the Publisher, Editors, and Editorial Board, neither does the publication of advertisements constitute any endorsement by the Publisher, Editors, and Editorial Board of the products or services advertised. The Publisher, Editors, Editorial Board, Reviewers, Authors, and Affiliated Agents shall not be held responsible or in any way liable for the continued accuracy of the information or for any errors, inaccuracies, or omissions of any kind in this publication, whether arising from negligence or otherwise, or for any consequences arising thereafter.

Copyright: © 2018 Pulse Marketing & Communications, LLC. All rights reserved. No part of this publication may be reproduced, stored, or transmitted in any form or by any means without the prior permission in writing from the Publisher. Requests should be addressed to the Permissions Editor at: Pulse Marketing & Communications, LLC, 4 Peninsula Avenue, Sea Bright, NJ 07760.

Abstracting & Indexing: The journal is indexed in Index Medicus/MEDLINE.

**Editorial**

<b>MANAGING EDITOR</b> Marla Kipp <a href="mailto:marla@skinmedjournal.com">marla@skinmedjournal.com</a>	<b>COPYEDITOR</b> Carrie Walker
<b>MEDIA WEB DIRECTOR</b> Joan Osgoodby <a href="mailto:joan@skinmedjournal.com">joan@skinmedjournal.com</a>	<b>COMPOSITION</b> Paul Bennett <a href="mailto:paul@skinmedjournal.com">paul@skinmedjournal.com</a>

**Publishing**

<b>PUBLISHER</b> Art Kalaka	<b>ASSOCIATE PUBLISHER</b> James R. Adams <a href="mailto:jadams@skinmedjournal.com">jadams@skinmedjournal.com</a>
--------------------------------	--

**Corporate**

<b>PRESIDENT</b> Arthur Kalaka <a href="mailto:akalaka@skinmedjournal.com">akalaka@skinmedjournal.com</a>	<b>CHIEF EXECUTIVE OFFICER</b> Jo-Ann Kalaka-Adams <a href="mailto:jadams@skinmedjournal.com">jadams@skinmedjournal.com</a>
---	---

**GENERAL COUNSEL**

Marianne Mckenzie  
[mmckenzie@skinmedjournal.com](mailto:mmckenzie@skinmedjournal.com)

Pulse Marketing & Communications, LLC  
4 Peninsula Avenue • Suite 401 • Sea Bright, NJ 07760  
Tel (732) 747-6525 • Fax (732) 747-7010

An Official Publication of



Chinese Society of Dermatology



The International Academy of Cosmetic Dermatology



The Section on Dermatology College of Physicians of Philadelphia



International Association of Ecological Dermatology (Eco-Derm)



The History of Dermatology Society



Philippine Academy of Clinical and Cosmetic Dermatology



Association of Cutaneous Surgeons



Maltese Association of Dermatology and Venereology



Lebanese Dermatological Society



Belarusian Society of Dermatovenereologists and Cosmetologists



North American Clinical Dermatologic Society



African Association for Dermatology



The Dermatologic & Aesthetic Surgery International League



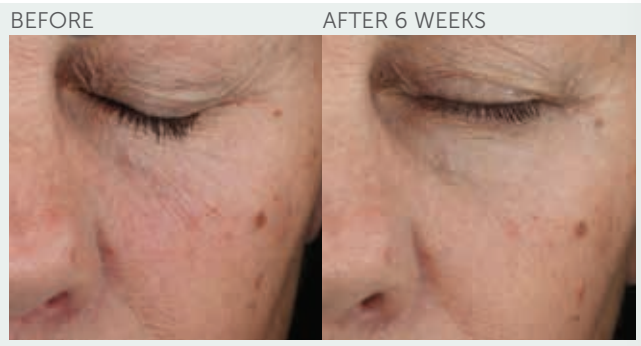Dermatology Insights and Inquiries

INTRODUCING

# Retinol*forte* Treatment Serum

**Fast and long acting retinol,  
without irritation**

Clinically proven in just 6 weeks\*:



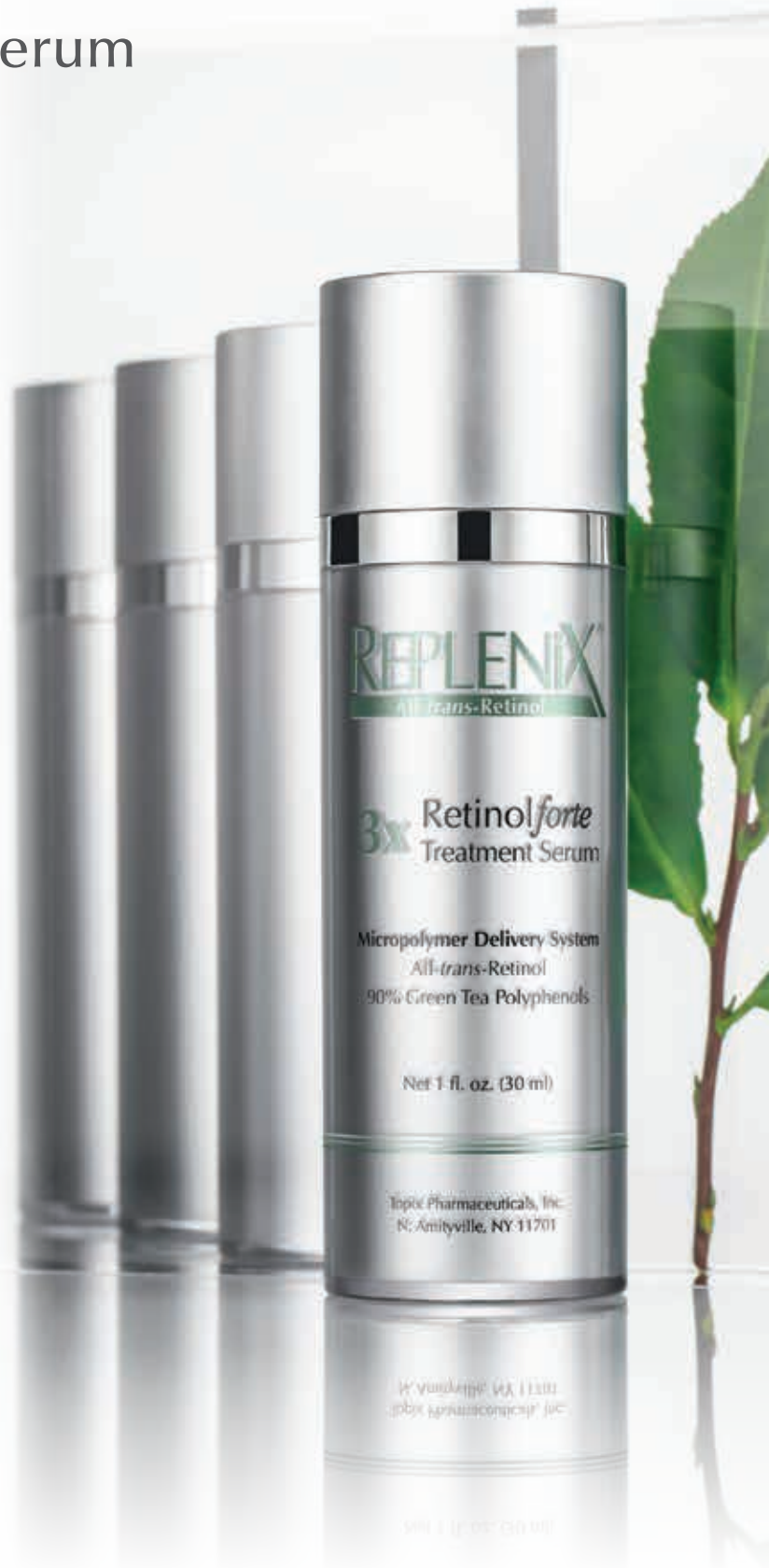**92%** of patients had an  
**improvement in fine lines**

**100%** of patients had  
**improved facial clarity**

**100%** of patients said  
**skin is visibly smoother**

Unique, patent-pending delivery system paired with soothing Green Tea Polyphenols quickly delivers retinol into skin and continuously releases over time, without irritation.

Available in 6 strengths.



\*Data on file

Call today to learn more about our Micro-Branded Skin Care Innovations™  
800-445-2595, ext 346 | [topixpharm.com](http://topixpharm.com)

**TOPIX**  
PHARMACEUTICALS, INC.

---

**EDITOR IN CHIEF**


---



**Lawrence Charles Parish, MD, MD (Hon)**

*Philadelphia, PA*

---

**DEPUTY EDITORS**


---

**William Abramovits, MD**

*Dallas, TX*

**Aditya K. Gupta, MD, PhD, FRCPC**

*London, Ontario, Canada*

**W. Clark Lambert, MD, PhD**

*Newark, NJ*

**Vesna Petronic-Rosic, MD, MSc**

*Chicago, IL*

**Larry E. Millikan, MD**

*Meridian, MS*

**Marcia Ramos-e-Silva, MD, PhD**

*Rio de Janeiro, Brazil*

**Jennifer L. Parish, MD**

*Philadelphia, PA*

---

**EDITORIAL BOARD**


---

Mohamed Amer, MD  
*Cairo, Egypt*

Robert L. Baran, MD  
*Cannes, France*

Anthony V. Benedetto, DO  
*Philadelphia, PA*

Brian Berman, MD, PhD  
*Miami, FL*

Mark Bernhardt, MD  
*Ft. Lauderdale, FL*

Jack M. Bernstein, MD  
*Dayton, OH*

Sarah Brenner, MD  
*Tel Aviv, Israel*

Henry H.L. Chan, MB, MD, PhD,  
FRCP

*Hong Kong, China*

Joel L. Cohen, MD  
*Greenwood Village, CO*

Natalie M. Curcio, MD, MPH  
*Nashville, TN*

Richard L. Dobson, MD  
*Mt Pleasant, SC*

William H. Eaglstein, MD  
*Menlo Park, CA*

Charles N. Ellis, MD  
*Ann Arbor, MI*

Howard A. Epstein, PhD  
*Philadelphia, PA*

Ibrahim Hassan Galadari, MD, PhD,  
FRCP

*Dubai, United Arab Emirates*

Anthony A. Gaspari, MD  
*Baltimore, MD*

Michael Geiges, MD  
*Zurich, Switzerland*

Michael H. Gold, MD  
*Nashville, TN*

Lowell A. Goldsmith, MD, MPH  
*Chapel Hill, NC*

Seung-Kyung Hann, MD, PhD  
*Seoul, Korea*

Roderick J. Hay, BCh, DM, FRCP,  
FRCPATH

*London, UK*

María Daniela Hermida, MD  
*Buenos Aires, Argentina*

Warren R. Heymann, MD  
*Camden, NJ*

Tanya R. Humphreys, MD  
*Bala-Cynwyd, PA*

Camila K. Janniger, MD  
*Englewood, NJ*

Ayse Serap Karadag, MD  
*Istanbul, Turkey*

Abdul-Ghani Kibbi, MD  
*Beirut, Lebanon*

Andrew P. Lazar, MD  
*Washington, DC*

Jasna Lipozencic, MD, PhD  
*Zagreb, Croatia*

Ada Lo Schiavo, MD  
*Naples, Italy*

Eve J. Lowenstein, MD, PhD  
*New York, NY*

George M. Martin, MD  
*Kihei, HI*

Marc S. Micozzi, MD, PhD  
*Rockport, MA*

Venkataram Mysore, MD,  
FRCP (Hon, Glasgow)

*Bangalore, India*

Oumeish Youssef Oumeish,  
MD, FRCP

*Amman, Jordan*

Joseph L. Pace, MD, FRCP  
*Naxxar, Malta*

Art Papier, MD  
*Rochester, NY*

Johannes Ring, MD, DPhil  
*Munich, Germany*

Roy S. Rogers III, MD  
*Scottsdale, AZ*

Donald Rudikoff, MD  
*New York, NY*

Robert I. Rudolph, MD  
*Wyomissing, PA*

Todd E. Schlesinger, MD  
*Charleston SC*

Virendra N. Sehgal, MD  
*Delhi, India*

Charles Steffen, MD  
*Oceanside, CA*

Alexander J. Stratigos, MD  
*Athens, Greece*

James S. Studdiford III, MD  
*Philadelphia, PA*

Robert J. Thomsen, MD  
*Los Alamos, NM*

Julian Trevino, MD  
*Dayton, OH*

Maria M. Tsoukas, MD, PhD  
*Chicago, IL*

Graham Turner, PhD, CBIOL, FSB  
*Port Sunlight, UK*

Snejina Vassileva, MD, PhD  
*Sofia, Bulgaria*

Daniel Wallach, MD  
*Paris, France*

Michael A. Waugh, MB, FRCP  
*Leeds, UK*

Wm. Philip Werschler, MD  
*Spokane, WA*

Ronni Wolf, MD  
*Rehovot, Israel*

Jianzhong Zhang, MD  
*Beijing, China*

Matthew J. Zirwas, MD  
*Columbus, Ohio*

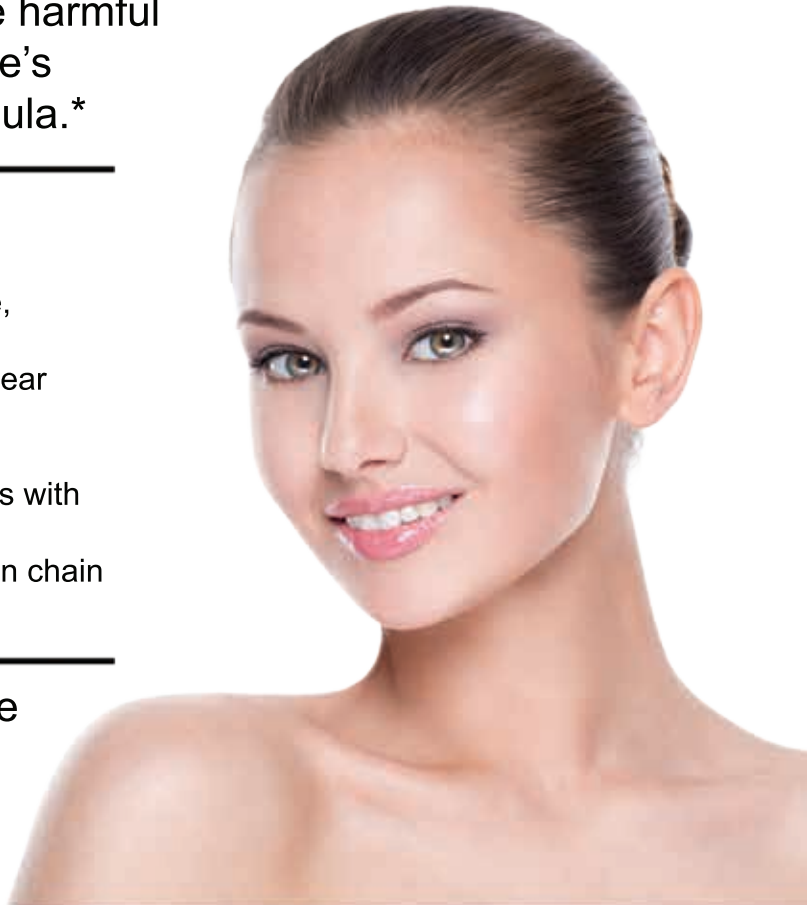

# POWERFUL, UNIQUE AND CLINICALLY PROVEN ANTI-OXIDANT FORMULA

Help your skin protect itself from the harmful effects of free radicals with Heliocare's exclusive, powerful antioxidant formula.\*

- **Free radicals can accelerate skin aging.**
- **Free radicals are everywhere.** Sun exposure, pollution, exercise and the environment are all common ways we are exposed every day all year round.
- **Antioxidants can help.** Providing free radicals with antioxidants to replace their missing electrons puts a stop to the damaging oxidation chain reaction.

Use Heliocare daily to promote more resilient, younger-looking skin.\*



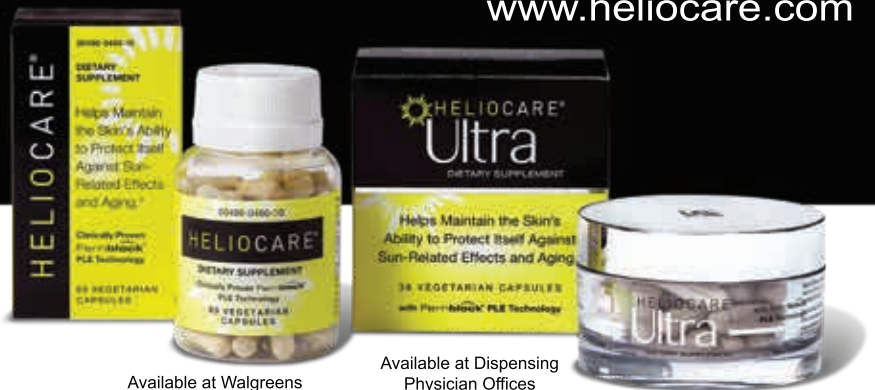**Heliocare's improved capsules are now:**

- Vegan
- Gluten-Free
- Free of Artificial Dyes

**For Samples,  
Coupons, or Patient  
Education Brochures  
Call: 866-668-7482**

## HELIOCARE®

[www.heliocare.com](http://www.heliocare.com)



Available at Walgreens

Available at Dispensing  
Physician Offices

**FERNDALE**  
HEALTHCARE INC.

\*These statements have not been evaluated by the Food and Drug Administration. This product is not intended to diagnose, treat, cure, or prevent any disease.

## EDITORIAL

# Fake News, Predatory Journals, Case Reports, Biostatistics, and Other Journalistic Musings—Part 1

Warren R. Heymann, MD

**W**e live in an era of information excess delivered by print, digital devices, webcasts, podcasts, and Tweets. Time for reflection is minimal. One of the major precipitants of physician burnout is the endless electronically documenting data, which has replaced speaking to and examining patients, and most importantly thinking about their problems.

Pressure abounds when sorting through the onslaught of data to find what is relevant and true. For those in academia, the need for publication remains undiminished, fueling the cycle further. Although IBM's Watson can absorb infinite information, unfortunately the glorious human brain can only assimilate a fraction of the data, and its interpretation is compounded by personal bias.

As we have learned, fake news site can generate fabricated stories that can yield devastating consequences when presented as fact.

## **PREDATORY JOURNALS**

Predatory journals have proliferated exponentially, soliciting publications (at a hefty fee). Young academicians may be particularly vulnerable, facing the "publish or perish" scenario. The problem is that many journals will literally publish anything that comes their way. This dilutes the quality of the body of medical literature; indeed, when one is accessing information at point-of-care, the reader can only assume that what was published has been editorially peer reviewed, allowing for at least a modicum of validity.

I receive requests to publish in these journals daily. Although I chuckle when the requests come from other disciplines, such

as orthopedics, gastroenterology, or anesthesiology, the situation is not laughable. Out of curiosity, I responded to one journal's editors, inviting them to visit my website ([www.dermatology-insightsandinquiries.com](http://www.dermatology-insightsandinquiries.com)) and choose a contribution that they would find worthwhile. Their response was, "choose whatever you'd like." Think about that for a moment—whatever I'd like? I can only interpret that as they would publish whatever is sent to them, regardless of the content. How dangerous!

I wholeheartedly concur with the following:

Predatory journals must be deprived of the legitimacy afforded by inclusion in prestigious databases like PubMed. PubMed, operated by the National Library of Medicine, is heavily used by researchers and clinicians to search the medical literature. Efforts by predatory publishers to gain inclusion in the PubMed database through strategies such as purchasing journals that are already PubMed indexed must be thwarted.<sup>1</sup>

Unfortunately, the blog listing predatory journals, started by Jeffrey Beall at the University of Colorado, is no longer available. Cabell International of Beaumont, Texas is planning to develop its own blacklist this year.<sup>2</sup>

## **IMPACT FACTOR**

Journal content is changing, driven by the drive for a higher impact factor. The question is, impact for whom? I read journals for my personal impact factor—how will a paper affect the care I deliver to my patients? I am not decrying the importance of topics such as burden of skin disease or quality of life studies—they are vital for the survival of our specialty as we are facing economic duress. I would just prefer that these

From the Division of Dermatology, Department of Medicine and Department of Pediatrics, Cooper Medical School of Rowan University, Marlton, NJ

Address for Correspondence: Warren R. Heymann, MD, 100 Brick Road – Suite 306, Marlton, NJ 08053 • E-mail: [wrheyman@gmail.com](mailto:wrheyman@gmail.com)

studies be in a new, separate journal devoted to dermatoeconomics.

## CASE REPORTS

When I read, I go for the clinically relevant studies. I understand why case reports are considered the bottom shelf of the evidence-based pyramid. Despite that, I get more out of a good case report and review of the literature than the latest treatise on the economic burden of hidradenitis suppurativa. Educationally, I agree that:<sup>3-5</sup>

Selecting and writing a case report can sharpen critical and observational skills, improve medical writing, strengthen the ability to generate and defend a hypothesis, and increase understanding of patient-centered care. It can give students valuable experience with the editorial process, motivate them to take a scholarly view of their clinical work, and allow them to contribute to the medical literature.<sup>3</sup>

Should case reports be relegated to electronic publications, they will not get read unless someone is searching specifically for an identical case. Increasingly, case reports are published in “open access” journals for a substantial fee, which may be also burdensome for the author or their institution.

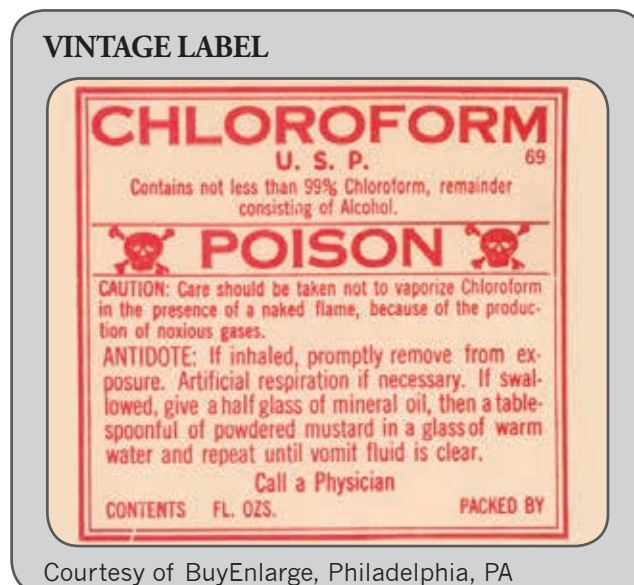## CONCLUSIONS

Dermatologists must become increasingly savvy about how they acquire new knowledge that affects patient care. Understanding when medical news is “fake,” appreciating the nature and pitfalls of predatory journals, considering the “personal” impact factor of a journal, and reading relevant case reports should enhance the quality of practice.

Part 2 will discuss biostatistics and other journalistic musings.

## REFERENCES

- 1 Benjamin HH, Weinstein DF. Predatory publishing: An emerging threat to the medical literature. *Acad Med.* 2017;92:150–151.
- 2 Singh Chawla D. Mystery as Controversial List of Predatory Publishers Disappears. January 17, 2017. <http://www.sciencemag.org/news/2017/01/mystery-controversial-list-predatory-publishers-disappears>. Accessed March 16, 2017.
- 3 Packer CD, Katz RB, Iacopetti CL, Krimmel JD, Singh MK. A case suspended in time: The educational value of case reports. *Academic Med.* 2017;92:152–156.
- 4 Petronic-Rosic V. O Case report: Where art thou? *SKINmed.* 2002;1:16–17.
- 5 Petronic-Rosic V. The power of one (I matter... Please report me): The case study. *SKINmed.* 2016;14:9–10.



# Brand Yourself, Grow Your Practice



## Micro-Branded Skin Care Innovations™

### Build Patient Loyalty

99% of patients are more likely to purchase a product with the doctor's name on it<sup>1</sup>  
79% of patients who purchase micro-branded skin care convert to other in-office procedures<sup>1</sup>

### Add Credibility to the Practice

91% of patients believe micro-branded products surpass the quality of those purchased OTC or online<sup>1</sup>

### Offer Exclusivity

Practices estimate an average of two additional visits per year from patients who use micro-branded products versus those who do not<sup>2</sup>

References: 1. Denova Research and True Skin Care Center 2. 2015 Survey of practices with private-label products. Data on file.

Call today to learn more 800-445-2595, ext 346  
topixpharm.com

**TOPIX**  
PHARMACEUTICALS, INC.

## COMMENTARY

# Media and the Skin

Jacob Johanssen, PhD; Diana Garrisi, PhD

A new study conducted by the University of Texas found that classic Hollywood film villains are statistically more likely to display a skin condition affecting their appearance. The results indicate that six of the all-time top 10 American film antiheroes have dermatologic findings including alopecia (30%), periorbital hyperpigmentation (30%), deep rhytides on the face (20%), multiple scars on the face (20%), verrucae vulgaris on the face (20%), and rhinophyma (10%).<sup>1</sup>

Julie Amthor Croley and colleagues dermatologically evaluated the American Film Institute's 100 Greatest Heroes and Villains list, concluding that skin conditions are used in film to emphasize the dichotomy of good and evil. Their 'patients' included the serial killer Hannibal Lecter in *The Silence of the Lambs* (1991), with androgenic alopecia (Norwood-Hamilton stage 3), and Darth Vader from *The Empire Strikes Back* (1980), displaying several scars, deep rhytides on the face, periorbital hyperpigmentation, and alopecia. The list also included two famous witches—the Wicked Witch of the West (*The Wizard of Oz*, 1939) and The Queen (*Snow White and the Seven Dwarfs*, 1937)—both of whom were associated with verruca vulgaris.

Conversely, heroes rarely show conditions severely affecting their appearance. The few exceptions include Rick Blaine (*Casablanca*, 1942), who has a scar on the lip, and Indiana Jones (*Raiders of the Lost Ark*, 1981), who has a small chin scar. A notable exception could also be the recent Hollywood superhero *Deadpool* (2016), who has scars on his face and body.

## SKIN AS A STORYTELLING DEVICE

As this research confirms, skin diseases can function to bring the narrative forward in Hollywood storytelling. Bodily deformities are employed not only to visually signify the immorality embodied by the villain, but also to give tangible proof of their evilness. Bodily signs make the antihero iconic and memorable. This is a very simple and quick plot device that aims to give unambiguous information to the audience about who they should identify with. It does not leave space for imagination or interpretation:

the lacerated face of Regan MacNeil in the *Exorcist* (1973) is not meant to prompt questions; the message is that when you meet the devil, you just know because it shows.

The disrupted face of evil is in direct contrast with the face of the hero or victim, whose immaculacy is exhibited as a reference to their ethical integrity. Skin conditions in cinema are metaphorically presented as a legal proof, the basis upon which the villain must be fought and defeated, leaving the audience happy and comfortable with that choice.

## FACIAL DISFIGUREMENT IN THE UK PRESS

Related to the theme of depictions of skin conditions in the media, we are working on a similar project at the Communication and Media Research Institute of the University of Westminster, London. We are currently looking at how facial disfigurement is covered in the UK press. Initial findings show that the news coverage of disfigurement may revert the hero-villain skin dichotomy. How? Most of the stories deals with acid-related attacks.

Acid attacks are a growing problem in the UK: statistics show that the number of admissions to hospital as a consequence of acid attacks rose by 50% between 2005 and 2015.<sup>2</sup> The narrative of the newspaper articles builds around the dichotomy of victim-attacker, where the former, whose face shows the wounds and scars left by the corrosive power of acid, is represented as the hero. Scars are then no longer a symbol of moral weaknesses as it happens in movies; on the contrary, the scar becomes the symbol of resistance and bravery. In addition, scars are used to provide documented legal evidence of the physical and psychological pain endured by the person attacked. A wide range of photographs is often displayed in the tabloid press, offering a chronological account of the stages of recovery and surgery from the day of the attack. In this way, the popular press reverses the trope of the face of evil identified by the team of researchers at the University of Texas in cinema. In common, the studies show that mass media still heavily rely on visual binary oppositions to represent human relationships.

From the Communication and Media Research Institute (CAMRI), University of Westminster, London, UK

Address for Correspondence: Diana Garrisi, University of Westminster, Communication and Media Research Institute (CAMRI), Harrow Campus, Watford Road, Northwick Park, Middlesex, HA1 3TP, UK • E-mail: dianagarrisi@yahoo.it

## CONCLUSIONS

Reality is seldom based on a binary system as there are gray areas. Even if we assume there is a mutually exclusive distinction between bad and good, it does not necessarily show. This is the reason why organizations such as the UK charity Changing Faces campaign to challenge stereotypical media representations of evilness based on physical appearance, in order to limit the possibilities of increasing the already high rates of prejudice and discrimination surrounding people who have a disfiguring condition. To this end, the UK saw the celebration of Face Equality

Day on May 26, 2017. This is the first organized national event created by Changing Faces to raise awareness of facial disfigurement and ensure that everyone is treated fairly and equally, whatever the appearance of their face or body.

## REFERENCES

- 1 Croley JA, Reese V, Wagner RF. Dermatologic features of classic movie villains. The face of evil. *JAMA Dermatol.* 2017;153:559–564.
- 2 Twoon M, Alethea T, Dziewulski P. Acid attacks: A growing problem in the UK. *Burns.* 2016;42:1156–1157.

### RASH DECISIONS

*Mark Bernhardt, MD, Section Editor*

I know a dermatologist who is very nice to his drug reps. He greets them warmly, asks about their personal lives, listens to their spiels. He happily accepts their samples and politely refuses blandishments like free dinners for him or comped lunches for his staff. When asked, he always assures his reps that he is using their drugs and writing “Brand Necessary” when he is reminded to do so. He’s a liar.

This dermatologist is a strong advocate of generic drugs and is appalled by the rapacious rise in drug costs he has seen over the 30+ years he has been in practice. He refuses to accept the pharmaceutical industry’s justification of their obscene prices as reflecting the high cost of bringing new drugs to market, noting that pharma spends as much on direct to consumer advertising as it does for research and development. (It’s because of these ubiquitous ads that this dermatologist has also stopped watching television, though that might be considered an unalloyed plus.) He is outraged that drugs which have been around for years and are long off-patent are now eye-wateringly expensive. He usually knows what medicines are best for his patients, but the challenge is finding an appropriate medicine they can afford. His most common patient complaint is when they call from the pharmacy asking if he has any idea how much the medicine he prescribed costs. He does.

So, this dermatologist takes the free samples offered by his reps and hands them out to his patients, knowing that if it works he will almost always write the prescription for the closest generic equivalent. He has never written “Brand Necessary.”

Should this dermatologist confess to his drug reps that he is giving out their samples but writing for the generic? If he does so, he will probably stop getting samples which he can distribute to his patients. Should he continue the charade, knowing that his reps can get his actual prescribing habits from the local pharmacies?

Can accepting free samples with no intention of providing the drug company any business be ethically justified? Can this dermatologist justify his less than truthful interactions with his drug reps by trying to protect his patients from the soaring cost of medicines?

Address for Correspondence: Mark Bernhardt, MD, Private Practice, 1601 East Broward Boulevard, Fort Lauderdale, FL 33301. E-mail:cheesedb@aol.com



## ORIGINAL CONTRIBUTION

# Novel Drugs Implicated in Pigmented Purpuric Dermatoses

Adaobi I. Nwaneshiudu, MD, PhD; Vesna Petronic-Rosic, MD, MSc

## ABSTRACT

We describe two cases of cutaneous eruptions of pigmented purpuric dermatoses (PPDs) arising after exposure to medications not previously reported in the literature as causing these reactions. Specifically, two women had biopsy-proven PPDs, one after exposure to an over-the-counter iodine supplement marketed as an extract from “Norwegian kelp,” and the other after intraocular injections of pegaptanib, a vascular endothelial growth factor inhibitor. The eruption occurred shortly after beginning the medication and resolved upon discontinuation. This highlights the importance of considering over-the-counter and intraocular medications when assessing cutaneous eruptions that may be medication related, such as PPDs. (*SKINmed*. 2018;16:13–17)

PPDs are a heterogeneous group of cutaneous eruptions characterized by pigmented, purpuric macules and papules. Five main clinical subtypes have been described:

- progressive pigmented purpura of Schamberg;
- pigmented purpuric lichenoid dermatosis of Gougerot and Blum;
- purpura annularis telangiectoides of Majocchi (PATM);
- eczematid-like purpura of Doucas and Kapetanakis;
- lichen aureus.<sup>1–3</sup>

Less commonly described entities include transitory PPD, unilateral linear PPD, granulomatous PPD, and itching purpura of Lowenthal.<sup>4,5</sup> Atypical clinical manifestations including unilateral, linear/blaschkoid, zosteriform, and granulomatous variants have also been described.<sup>6–8</sup> PPD variants are indistinguishable on histopathology. Schamberg disease is the most common variant, characterized by aggregates of pin-head-sized petechiae resembling cayenne pepper, usually on the lower extremities.<sup>9</sup>

Multiple triggers have been associated with PPD, including drugs, chemical ingestions, infections, and underlying hemato-

logic or systemic diseases. Specifically, multiple different medications have been implicated in the literature as the causative factor responsible for eruptions of PPD. We describe two unique cases of PPD arising in women after the use of an iodine supplement and a vascular endothelial growth factor inhibitor intraocular injection, respectively.

## CASE 1

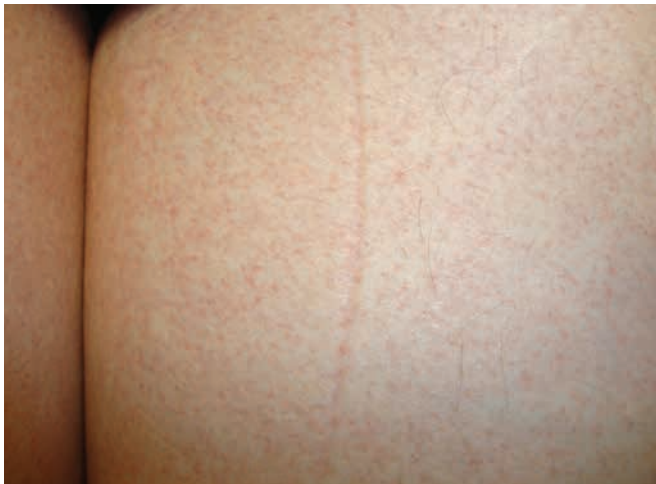A 36-year-old white woman presented with innumerable, minute, cayenne-pepper-like pigmented macules diffusely appearing on the trunk and extremities (Figure 1). These asymptomatic lesions had been present for months and were noticed shortly after starting an over-the-counter iodine supplement for subclinical hypothyroidism (Figure 2). A punch biopsy was taken from a lesion on the thigh to confirm the diagnosis.

Histopathologic analysis showed classic features of PPD with numerous extravasated red blood cells within the papillary dermis and a superficial perivascular lymphocytic infiltrate (Figure 3). The patient discontinued taking the supplement, which resulted in complete resolution of her skin eruption within 2 weeks. Based on clinical and pathologic findings, she was diagnosed with a drug-induced PPD, specifically the progressive pigmented purpura of Schamberg variant.

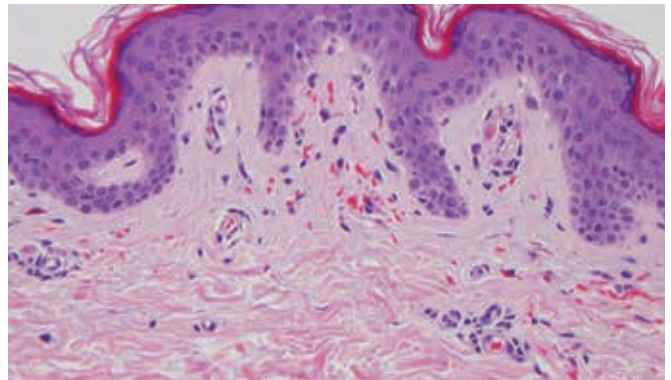
From the Section on Dermatology, University of Chicago Pritzker School of Medicine, Chicago, IL

Address for Correspondence: Adaobi I. Nwaneshiudu, MD, PhD, Section on Dermatology, University of Chicago Pritzker School of Medicine, 5841 South Maryland Avenue, MC 5067, Chicago, IL 60637

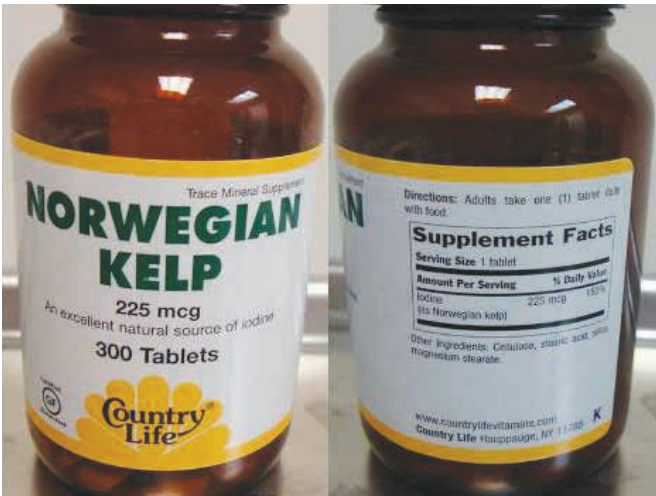• E-mail: adaobi.nwaneshiudu@uchospitals.edu



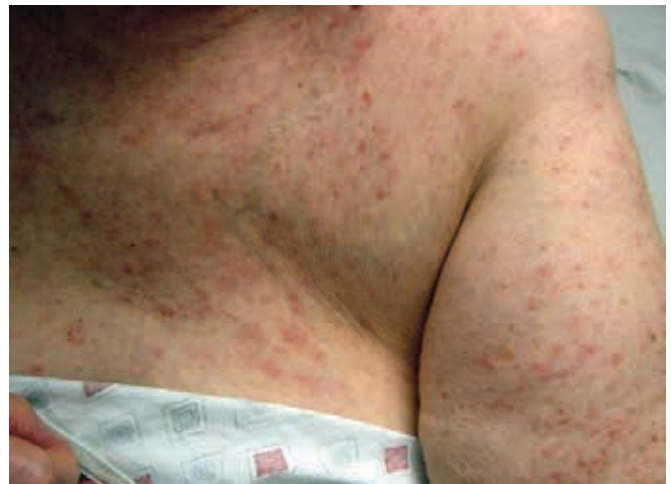**Figure 1.** Minute purpuric macules on the anterior aspect of the thigh.



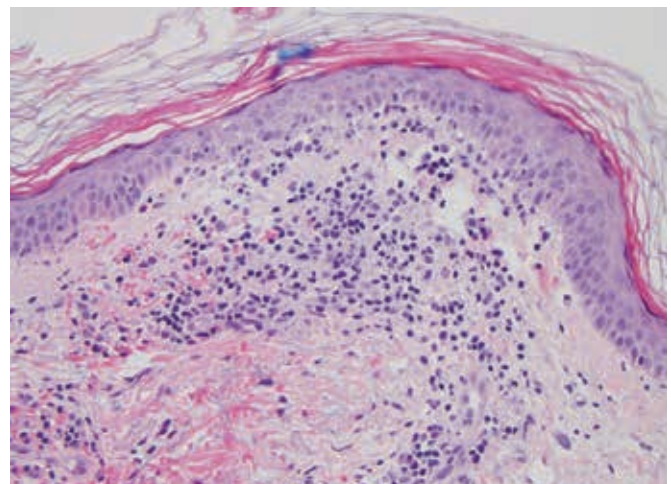
**Figure 3.** Mild perivascular lymphocytic infiltrate and extravasated red blood cells (hematoxylin and eosin stain, magnification  $\times 20$ ).



**Figure 2.** Iodine supplement taken for subclinical hypothyroidism.



**Figure 4.** Erythematous nonblanching macules and petechiae on the upper region of the trunk and extremities.



**Figure 5.** Patchy lichenoid dermatitis with extravasated red blood cells (hematoxylin and eosin stain, magnification  $\times 20$ ).

**CASE 2**

An 80-year-old white woman, with a history of Churg-Strauss syndrome, presented with diffuse, nonblanching erythematous macules and petechiae (Figure 4) a few days after the first dose of pegaptanib, a selective vascular endothelial growth factor antagonist, for macular degeneration. A biopsy was taken from a lesion on her arm to confirm the diagnosis. Histopathologic analysis showed attenuation of the epidermis, with basal layer vacuolization, and a patchy lichenoid infiltrate with rare eosinophils and extravasated erythrocytes (Figure 5).

A diagnosis of drug-induced PPD, most likely the pigmented, purpuric lichenoid dermatosis of Gougerot and Blum, was



made. The lesions resolved within a few weeks after completing the pegaptinib intraocular injections.

## DISCUSSION

PPDs are a heterogeneous group of eruptions with similar histopathologic characteristics. They tend to present clinically with petechiae and golden-brown, pigmented macules, papules, and plaques distributed symmetrically on the lower extremities, but can also be generalized.<sup>1,4</sup> PPD is known to occur in all races, with a predominance in men, except for the PATM variant, which is more common in women.<sup>1,10</sup> Lichen aureus is a rare form of PPD characterized by golden-brown, rust-colored macules or lichenoid papules usually on the lower legs of young adults, especially men, and less frequently in children. This variant may exhibit a segmental pattern, follow the lines of Blaschko or the course of an underlying vein.<sup>8</sup>

The majority of cases of PPD are benign cutaneous conditions with no systemic involvement, but they can have a chronic and relapsing course. A transitory idiopathic PPD variant resembling Schamberg disease, lasting less than 3 months, has been described in an otherwise healthy young woman, with no history of medication use or systemic disease. These authors noted that the onset of transitory PPD occurred during March-September, and suggested the possibility of an infectious etiology for this variant.<sup>11</sup>

The PPD variants all share similar histologic features of a perivascular lymphocytic infiltrate, sometimes described as a lymphocytic “capillaritis,” involving superficial vessels in the dermis without frank vasculitis. This perivascular infiltration results in vessel damage and extravasation of erythrocytes into the dermis, with hemosiderin deposition seen in older lesions. A lichenoid infiltrate can be seen in lichen aureus and the Gougerot and Blum variants, and may demonstrate clonal T-cell populations, without other cardinal features suggestive of a frank lymphoma.<sup>1,3,12</sup>

In a subset of patients, the lesions of PPD progress to cutaneous T-cell lymphoma, most commonly mycosis fungoides (MF), leading some experts to designate PPDs as cutaneous lymphoid dyscrasias.<sup>12</sup> Atypical PPDs appear similar to PPDs clinically but histologically show features associated with MF including Sézary cells, laminated dermal sclerosis, and epidermotropism.<sup>3,12,13</sup> This leads to diagnostic challenges as there are rare reports of PPD preceding MF, evidence of lymphoid atypia in lesions of typical PPD, and MF with purpuric features described in the literature. A possible existence of PPD/MF overlap has been suggested, with long-standing lesions that look like a reticular form

of MF but have the histologic findings of PPD, and these patients require regular follow-up.<sup>14</sup>

Although most cases of PPD are idiopathic, others have been linked to different factors including drugs, exercise, venous hypertension, gravity, infections, chemical exposures, and systemic illness, such as diabetes and antiphospholipid syndrome.<sup>1,15,16</sup> Various medications, food additives, and external contact agents, including clothing dyes, have also been implicated in the etiology of PPD.<sup>17–20</sup>

Drug-induced cases of PPD are typically transient, lasting up to 4 months, resolve with discontinuation of the medication, and are more likely to involve other body sites. A rechallenge with the same medication would cause a recurrence of the eruptions, facilitating verification of the causative agent in different studies.<sup>21,22</sup> A drug-based origin for PPD is therefore determined based on lesional onset and/or resolution after discontinuation of the offending agent. Intraepidermal Sézary cells are less frequent in biopsies of drug-related atypical PPD relative to idiopathic and MF-related atypical PPD, leading to the conclusion that atypical cases of PPD may be of drug-based origin, should not be equated with purpuric MF, and are not necessarily a precursor lesion of MF.<sup>12</sup>

Common culprit medications include diuretics and nonsteroidal anti-inflammatory drugs, but other drugs have been described including calcium-channel blockers, lipid-lowering agents,  $\beta$ -blockers, angiotensin-converting enzyme inhibitors, antihistamines, antidepressants, analgesics, sedatives, stimulants, antibiotics, cardiovascular drugs, and dietary supplements. Specifically, medications described in association with PPDs include sildenafil, medroxyprogesterone acetate, bupropion, glipizide, pseudoephedrine, phenothiazine, and creatine supplementation.<sup>19,23–26</sup> Most recently, a case of PATM due to isotretinoin has been described.<sup>5</sup>

Other ingested substances have been implicated in PPD eruptions, as exemplified in a case of widespread PPD lesions induced and rapidly provoked by dietary factors, specifically Coca-Cola and apple cherry fruit spritzer.<sup>27</sup> Lichen aureus has been reported in a child after regular consumption of an energy drink, resolving when the drink was stopped.<sup>28</sup>

Drug-induced PPD has been reported in cases with administration methods including ingestion by the oral route, topical application, and intramuscular and intravascular injections. For example, PPD resulting from the depot contraceptive medroxyprogesterone acetate in a teenage girl completely resolved within 8 weeks of stopping the injections.<sup>23</sup> An eruption of PPD due to

glipizide in a male patient resolved within 3 weeks of discontinuing the medication.<sup>18</sup> Bufexamac-induced allergic contact dermatitis with hematogenous dissemination presenting with the clinical and histological picture of PPD has also been described.<sup>24</sup> Topical fluorouracil has been associated with a PPD-like eruption.<sup>29</sup> Other medications reported to cause PPD include sedatives such as carbromal and meprobamate, vitamin B1, nitroglycerin, chlordiazepoxide, furosemide, and trichlomethiazole.<sup>30–32</sup>

PPD has been causally linked to pseudoephedrine ingestion.<sup>25</sup> Pseudoephedrine is typically a cause of a fixed drug eruption, especially the nonpigmented variant; however, these authors described a woman with pruritic purpuric plaques with some vesicles after taking 60 mg of pseudoephedrine and 10 mg of loratadine. The patient was rechallenged with loratadine, with negative results. Rechallenge with 15 mg of pseudoephedrine resulted, within 4 hours, in the same eruptions in the same sites as her previous attack. A patch test was also performed using pseudoephedrine and resulted in the same eruption. Biopsies of the positive patch test site and the cutaneous eruption after oral ingestion showed typical findings of PPD.<sup>25</sup> Although PPD eruptions resulting from different administration methods are present in the literature, intraocular medications have not, to the best of our knowledge, been previously described.

Treatment of drug-induced PPD includes stopping the offending medication, which may be sufficient to clear the eruption in most cases. Idiopathic PPD eruptions can be difficult to treat, and the use of topical steroids and compression stockings for the lower extremities in mild cases, with addition of oral vitamin C or pentoxifylline in moderate cases, has been described.<sup>8,12</sup> In severe or treatment-refractory cases, phototherapy including ultraviolet therapies (PUVA, and narrow-band UVB) and photodynamic therapy has been used, as well as systemic immunosuppressants such as cyclosporine or methotrexate.<sup>12,33,34</sup> Narrow-band UVB has proven especially useful in cases with widespread lesions and in treatment-resistant, symptomatic cases, with a sustainable response after a 1 year of follow-up.<sup>10</sup>

## CONCLUSIONS

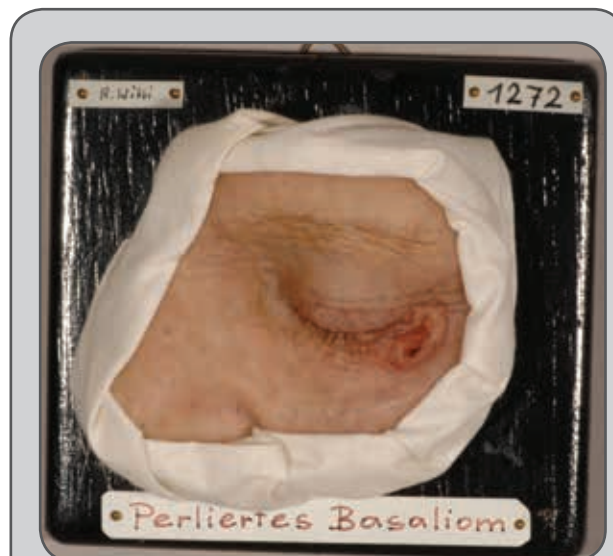We report two new causes of PPD, specifically an oral iodine supplement and an intraocular antivascular endothelial growth factor injection. The mechanism of the pathogenesis of drug-induced PPD is not clearly defined, but speculations include a direct toxic effect of the ingested substances or their metabolites on the capillaries, or an immune-mediated vascular injury due to the substance acting as a hapten leading to antigen formation.<sup>5</sup> Other speculations have been made on the effect of medications or their metabolites on the integrity of the vessel wall as

part of the pathogenesis of PPD. In drug-induced cases of PPD, stopping the offending medication if possible usually results in prompt resolution of the eruption, as was noted in our patients.

## REFERENCES

- 1 Miller K, Fischer M, Kamino H, Meehan S, Cohen D. Purpura annularis telangiectoides. *Dermatol Online J*. 2012;18:5.
- 2 Majocchi D. Sopra una dermatosis non ancora descritta, "purpura annularis telangiectode." *G Ital Mal Venereol*. 1896;31:263.
- 3 Magro CM, Schaefer JT, Crowson AN, Li J, Morrison C. Pigmented purpuric dermatosis: Classification by phenotypic and molecular profiles. *Am J Clin Pathol*. 2007;128:218–229.
- 4 Sardana K, Sarkar R, Sehgal VN. Pigmented purpuric dermatoses: An overview. *Int J Dermatol*. 2004;43:482–488.
- 5 Kaplan R, Meehan SA, Leger M. A case of isotretinoin-induced purpura annularis telangiectodes of majocchi and review of substance-induced pigmented purpuric dermatosis. *JAMA Dermatol*. 2014;150:182–184.
- 6 Mar A, Fergin P, Hogan P. Unilateral pigmented purpuric eruption. *Australas J Dermatol*. 1999;40:211–214.
- 7 Wong WR, Kuo TT, Chen MJ, Chan HL. Granulomatous variant of chronic pigmented purpuric dermatosis: Report of two cases. *Br J Dermatol*. 2001;145:162–164.
- 8 Moche J, Glassman S, Modi D, Grayson W. Segmental lichen aureus: A report of two cases treated with methylprednisolone aceponate. *Australas J Dermatol*. 2011;52:e15–e18.
- 9 Fathy H, Abdelgaber S. Treatment of pigmented purpuric dermatoses with narrow-band UVB: A report of six cases. *J Eur Acad Dermatol Venereol*. 2011;25:603–606.
- 10 Sharma L, Gupta S. Clinicoepidemiological study of pigmented purpuric dermatoses. *Indian Dermatol Online J*. 2012;3:17–20.
- 11 Abe M, Syuto T, Ishibuchi H, Yokoyama Y, Ishikawa O. Transitory pigmented purpuric dermatoses in a young Japanese female. *J Dermatol*. 2008;35:525–528.
- 12 Crowson AN, Magro CM, Zahorchak R. Atypical pigmentary purpura: A clinical, histopathologic, and genotypic study. *Hum Pathol*. 1999;30:1004–1012.
- 13 Lipsker D. The pigmented and purpuric dermatitis and the many faces of mycosis fungoides. *Dermatology*. 2003;207:246–247.
- 14 Zalaudek I, Ferrara G, Brongo S, Giorgio CM, Argenziano G. Atypical clinical presentation of pigmented purpuric dermatosis. *J Dtsch Dermatol Ges*. 2006;4:138–140.
- 15 Yildiz F, Tas DA, Açikalin A, et al. Pigmented purpuric dermatosis associated with primary antiphospholipid syndrome. *Intern Med*. 2013;52:1255–1257.
- 16 Sawamura D, Ohata Y, Shibaki A, Shimizu H. Pigmented purpuric dermatosis in mixed cryoglobulinaemia associated with rheumatoid arthritis and hepatitis C infection. *Acta Derm Venereol*. 2005;85:460–461.

- 17 Yung A, Goulden V. Pigmented purpuric dermatosis (capillaritis) induced by bezafibrate. *J Am Acad Dermatol*. 2005;53:168–169.
- 18 Adams BB, Gadenne AS. Glipizide-induced pigmented purpuric dermatosis. *J Am Acad Dermatol*. 1999;41:827–829.
- 19 Koçak AY, Akay BN, Heper AO. Sildenafil-induced pigmented purpuric dermatosis. *Cutan Ocul Toxicol*. 2013;32:91–92.
- 20 Satoh T, Yokozeki H, Nishioka K. Chronic pigmented purpura associated with odontogenic infection. *J Am Acad Dermatol*. 2002;46:942–944.
- 21 Pang BK, Su D, Ratnam KV. Drug-induced purpura simplex: Clinical and histological characteristics. *Ann Acad Med Singapore*. 1993;22:870–872.
- 22 Ratnam KV, Su WP, Peters MS. Purpura simplex (inflammatory purpura without vasculitis): A clinicopathologic study of 174 cases. *J Am Acad Dermatol*. 1991;25:642–647.
- 23 Rose RF, Bishop R, Goulden V. Pigmented purpuric dermatosis as a delayed reaction to medroxyprogesterone acetate. *J Eur Acad Dermatol Venereol*. 2008;22:1150–1151.
- 24 Waltermann K, Marsch WCh, Kreft B. Bufexamac-induced pigmented purpuric eruption. *Hautarzt*. 2009;60:424–427.
- 25 Díaz-Jara M, Tornero P, Barrio MD, et al. Pigmented purpuric dermatosis due to pseudoephedrine. *Contact Dermatitis*. 2002;46:300–301.
- 26 Chorny JA, Cohen J. Pigmented purpuric dermatosis associated with creatine supplementation. *Arch Dermatol*. 2006;142:1662–1663.
- 27 Weiß KT, Karrer S, Landthaler M, Babilas P, Schreml S. Diet-induced pigmented purpuric dermatosis. *Australas J Dermatol*. 2014;55:e51–e53.
- 28 Yazdi AS, Mayser P, Sander CA. Lichen aureus with clonal T cells in a child possibly induced by regular consumption of an energy drink. *J Cutan Pathol*. 2008;35:960–962.
- 29 Voelter WW. Pigmented purpuric dermatosis-like reaction to topical fluorouracil. *Arch Dermatol*. 1983;119:875–876.
- 30 Peterson WC Jr, Manick KP. Purpuric eruptions associated with use of carbromal and meprobamate. *Arch Dermatol*. 1967;95:40–42.
- 31 Nishioka K, Sarashi C, Katayama I. Chronic pigmented purpura induced by chemical substances. *Clin Exp Dermatol*. 1980;5:213–218.
- 32 Nishioka K, Katayama I, Masuzawa M, Yokozeki H, Nishiyama S. Drug-induced chronic pigmented purpura. *J Dermatol*. 1989;16:220–222.
- 33 Kim SK, Kim EH, Kim YC. Treatment of pigmented purpuric dermatosis with topical photodynamic therapy. *Dermatology*. 2009;219:184–186.
- 34 Seckin D, Yazici Z, Senol A, Demircay Z. A case of Schamberg's disease responding dramatically to PUVA treatment. *Photodermatol Photoimmunol Photomed*. 2008;24:95–96.



“Perliertes Basaliom”, Moulage No. 1272, made in the Clinic for Dermatology Zurich. Museum of Wax Moulages Zurich, [www.moulagen.ch](http://www.moulagen.ch)

Courtesy of Michael Geiges, MD

# Botulinum Toxins:

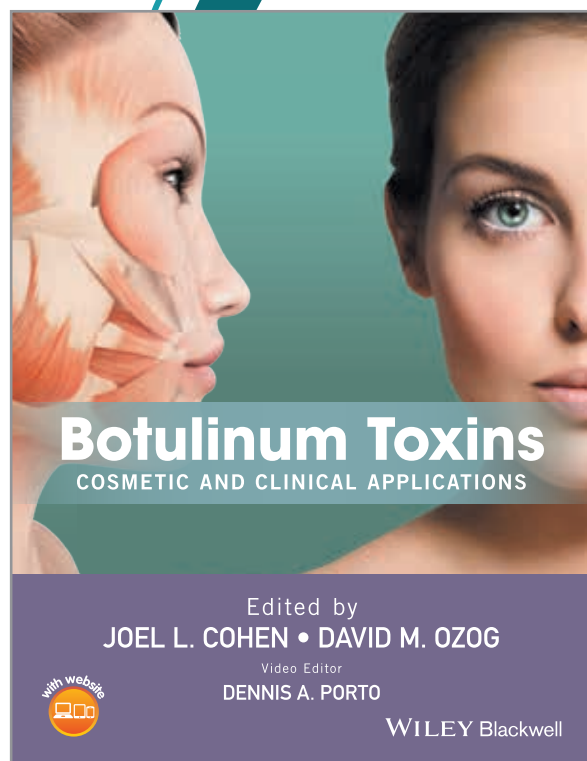
## COSMETIC AND CLINICAL APPLICATIONS

Edited by Joel L. Cohen and David M. Ozog  
Video Editor: Dennis Porto

Use code **VBN58** to save **25%** at [www.wiley.com](http://www.wiley.com)

*Botulinum Toxins: Cosmetic and Clinical Applications* provides a comprehensive and in-depth review of the use of botulinum toxin for esthetic procedures and medical applications as a stand-alone treatment and as combination therapy with other non-surgical procedures.

- Benefits from a wealth of color images, procedural videos, and expert tips and tricks
- Takes a region oriented approach, providing guidance on treatment of the glabella, forehead, periocular and perioral areas, plus contouring of the lower face, lower leg and calf, and neck rejuvenation
- Contains a thorough review of non-cosmetic treatments such as correction of facial asymmetry and treatment of axillary hyperhidrosis, plus palm, sole, and craniofacial hyperhidrosis
- Covers exciting new topics, such as future injectables, topical botulinum toxin, and facial contouring including treatment for benign masseter hypertrophy
- Includes considerations for darker skin types



9781444338256 | 392 pages | Fall 2017  
\$199.95, £139.99, €182.00



Also available  
as an eBook

For further information please go to  
[www.wiley.com](http://www.wiley.com)

WILEY

## ORIGINAL CONTRIBUTION

# Salivary Cortisol and Salivary Flow Rate in Clinical Types of Oral Lichen Planus

Arash Mansourian, DDS, MSc; Shamsoulmolouk Najafi, DDS, MSc; Nazila Nojoumi, DDS; Parisa Parhami, DDS; Mahdieh-Sadat Moosavi, DDS, MSc

## ABSTRACT

Patients with oral lichen planus (OLP) may develop immune sialadenitis that causes a dry mouth. The role of cortisol in autoimmune diseases is well known; yet studies on this subject are controversial. In this study, the salivary flow rate and salivary cortisol level were compared among subtypes of OLP. This study involved three groups of patients: (1) 11 with reticular OLP, (2) 20 with atrophic-erosive OLP, and (3) 30 with no apparent oral lesion. The salivary flow rate in the control group was significantly higher than in OLP patients. The mean level of cortisol in atrophic-erosive cases was higher than in reticular cases and in the control group; however, there was no significant difference between the three study groups. In a previous study, there was moderate to severe acinar atrophy in two-thirds of patients with OLP, which may explain the decreased salivary flow rate in these patients. (*SKINmed*. 2018;16:19–22)

Studies have evaluated the salivary cortisol level in individuals with lichen planus, but there is no comprehensive study evaluating the salivary cortisol level in subtypes of OLP. Higher autoantibody levels in autoimmune connective tissue diseases are accompanied by elevated cortisol levels. It can be concluded that, in the atrophic-erosive type of OLP, higher salivary cortisol concentrations may reflect higher circulating autoantibody levels. The flow rate of saliva was lower in OLP subjects compared to control participants, which suggests hyposalivation in OLP patients. Although the salivary cortisol level was relatively higher in patients with OLP, a significant association between salivary cortisol level and OLP was not observed.

Lichen planus is a chronic inflammatory mucocutaneous disease, which frequently manifests in the oral mucosa.<sup>1–4</sup> Oral lesions are categorized as reticular, papular, bullous, erosive-ulcerative, atrophic (erythematous), and plaque-like lesions.<sup>5,6</sup>

Xerostomia and decreased salivary flow rate have been reported in OLP,<sup>7,8</sup> but controversies exist regarding this.<sup>9</sup> OLP patients may develop immune sialadenitis that causes a dry mouth, which was at first thought to be Sjögren's syndrome. Therefore

salivary gland dysfunction in OLP has been proposed.<sup>7</sup> One of the aims of this study was the evaluation of salivary flow rate in such patients.

Xerostomia may exist despite normal salivary flow rate. Changes in the quality of saliva that occur in salivary gland dysfunction can cause xerostomia.<sup>7</sup> One of the possible salivary compositional changes may be of cortisol; cortisol plays a significant role in regulating the immunologic and inflammatory responses.<sup>10</sup> Salivary cortisol level is a better indicator than the serum cortisol level because salivary cortisol is not bound to albumin or corticosteroid-binding globulin, as it is in the serum. In addition, collection of saliva samples is more convenient and noninvasive.<sup>11,12</sup>

Although the role of cortisol in autoimmune diseases is well known, studies on this subject have been controversial.<sup>13–15</sup> Previous studies have assessed the salivary level of cortisol in lichen planus, but there is no study evaluating the salivary level of cortisol in different subtypes of this disease. Therefore this study compared salivary cortisol level among atrophic-erosive and reticular types of OLP.

From the Department of Oral Medicine, School of Dentistry, Tehran University of Medical Sciences, Tehran, Iran

Address for Correspondence: Mahdieh-Sadat Moosavi, DDS, MSc, Department of Oral Medicine, School of Dentistry, Dental Research Center, Tehran University of Medical Sciences, North Karegar Street, Tehran, Iran 14399-55991 • E-mail: ms-moosavi@sina.tums.ac.ir

## MATERIALS AND METHODS

This case-control study involved 61 patients seen in the department of oral and maxillofacial medicine. All participants provided written informed consent before samples were collected. The participants were divided into three groups:

- Group 1: 11 patients with histopathologically confirmed reticular-type OLP, with a mean age of 54 years.
- Group 2: 20 patients with histopathologically confirmed atrophic-erosive OLP, with a mean age of 51 years.
- Group 3: 30 patients with no apparent lesion on the oral mucosa, with a mean age of 40 years.

Patients with systemic diseases, autoimmune disorders, hepatitis, HIV, infection, renal disease, oral lichenoid reactions, or a history of taking autoimmune, systemic, or local medications were excluded from the study, as were pregnant women and nursing mothers.

Unstimulated saliva samples were collected between 9 and 11 AM. All the subjects were asked to refrain from oral intake, tooth brushing, smoking, and using any mouthwash for at least 90 minutes before collection of the saliva sample. During sample collection, the lips were cleaned of any cosmetic products. Participants were first asked to stay in a resting position and swallow all the saliva in their mouth, lean their heads forward for 15 minutes, and then spit the accumulated saliva into the sterilized

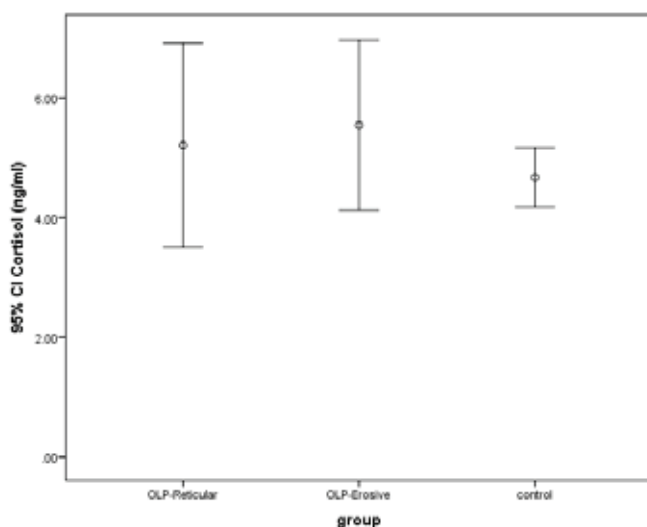
tubes. The samples were then centrifuged at 2000 rpm for 10 minutes. The supernatant fluid was frozen at  $-20^{\circ}\text{C}$  until further analysis. The salivary cortisol level of the samples was determined using a salivary cortisol enzyme-linked immunosorbent assay kit.

Quantitative data were presented as means $\pm$ SD. One-sided variant analysis was used for the comparison between the three study groups. The Games-Howell test was used for paired comparison between study groups. The level of significance was set at  $<.05$ .

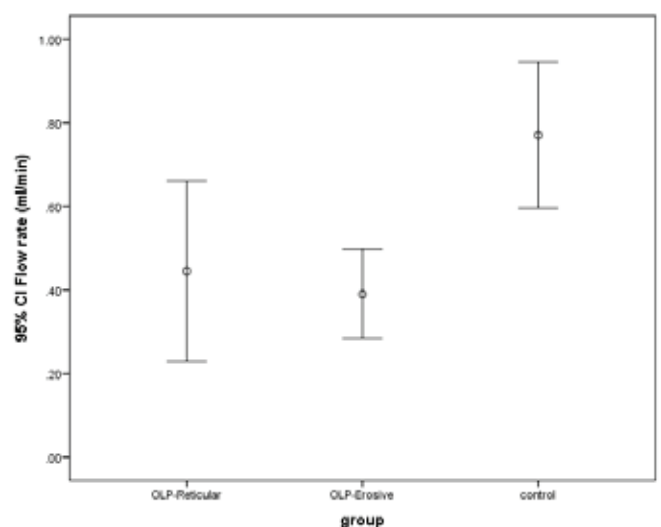
## RESULTS

The basic characteristics and the mean of unstimulated salivary cortisol level and salivary flow rates in the study groups are displayed in the Table. The means and 95% confidence intervals for unstimulated salivary cortisol level and salivary flow rates are shown in Figures 1 and 2.

Although the mean level of cortisol in atrophic-erosive disease was higher than in reticular disease and in the control group, there was no significant difference in the mean cortisol level between the three study groups ( $P=.39$ ). In addition, the flow of unstimulated saliva was not the same in the study groups ( $P=.002$ ), in that the flow rate in the control group was significantly higher than that in OLP patients. There was no significant difference between the two subtypes of OLP (groups 2 and 3) regarding salivary flow rate ( $P=0.87$ ).



**Figure 1.** Mean and 95% confidence intervals (CI) of unstimulated salivary cortisol level.



**Figure 2.** Mean and 95% confidence intervals (CI) of unstimulated salivary flow rates.

**Table. Study Group Mean of Unstimulated Salivary Cortisol Level and Salivary Flow Rates**

	RETICULAR OLP N=11 (4 MEN, 7 WOMEN)	ATROPHIC-EROSIVE OLP N=20 (5 MEN, 15 WOMEN)	CONTROL GROUP N=30 (20 MEN, 10 WOMEN)	P VALUE
Unstimulated salivary cortisol level (ng/mL)	5.21±2.54	5.55±3.03	4.67±1.33	0.39
Flow rate (mL/min)	0.44±0.32	0.39±0.23	0.77±0.47	0.002

Abbreviation: OLP, oral lichen planus.

## DISCUSSION

Reticular is the most common subtype of OLP;<sup>16</sup> however, more patients with atrophic-erosive than reticular disease were included in this study. This might be because the pain and burning sensation seen in the atrophic-erosive disease lead to more patients being referred to dental clinics.

The salivary flow rate in OLP patients was significantly less than that in controls, but there were no significant differences between the two subtypes of OLP. The different findings in the salivary flow rate of OLP in other studies<sup>6,7</sup> might be explained by differences in saliva collection methods and times of collection. It has been determined that unstimulated salivary flow rate is regulated by a circadian rhythm, being low at approximately 6 AM and high at around 6 PM.<sup>17</sup> Therefore, in the current study, the time of collection was set to be the same for all participants (between 9 and 11 AM).

In the previous study, labial salivary gland biopsy showed moderate to severe acinar atrophy in two-thirds of patients with OLP, which is consistent with our result;<sup>18</sup> however, sample size was small, and further studies are needed to find a relationship between structural changes in salivary glands and diminished salivary flow rate in OLP.

Oral mucosa and skin have the same wound healing phases, but healing occurs more rapidly and with less scar formation in the oral cavity. Several factors influence the faster wound healing of the oral mucosa. For example, there is a higher baseline turnover of cells in the oral cavity than the skin. The presence of saliva is another important factor. Saliva creates a humid environment and contains important proteins that play a role in epithelial healing, such as epidermal growth factor, secretory leukocyte protease inhibitor, and especially histatin.<sup>19</sup> Thus a decrease in salivary flow rate may affect the healing of injured or lesional mucosa, which can exacerbate the chronicity of OLP. An assessment of hyposalivation in OLP may therefore be beneficial for treatment as well as understanding of disease etiology.

The cell-mediated immune system provides the most important contribution to the development of OLP.<sup>20</sup> Cortisol plays a significant role in regulating the immune system response and activating the sympathetic nervous system.<sup>6,16,21,22</sup> Salivary cortisol tracks the circadian variation of serum cortisol, with the highest levels in the morning.<sup>23</sup>

In the current study, salivary cortisol level was higher in patients with OLP than control participants. In addition, salivary cortisol level was higher in atrophic-erosive disease than reticular disease, although there was no significant difference between the three study groups ( $P>.05$ ). The higher salivary cortisol level in the OLP group was in accordance with the results of other studies.<sup>15,16,24</sup>

In one study, salivary cortisol levels were also higher in OLP but did not differ significantly between the OLP group and controls.<sup>13</sup> It seems that the finding of an insignificant or significant difference between OLP and control groups is related to the participants' psychological state. For example, in another study, cortisol levels were significantly higher in the OLP group, and these patients had significantly higher depression, anxiety, and stress scores.<sup>24</sup> Previous studies have evaluated the salivary cortisol level in lichen planus,<sup>13,14,25</sup> but the aim of this study was to compare salivary cortisol level in subtypes of OLP. The higher salivary cortisol levels seen in erosive OLP may be related to activation of hypothalamic-pituitary-adrenal axis due to pain caused by the burning sensation of the erosive lesions.<sup>24</sup>

Higher autoantibody levels in autoimmune connective tissue diseases such as systemic lupus erythematosus are accompanied by elevated cortisol concentrations.<sup>26</sup> It can be concluded that the higher salivary cortisol levels of atrophic-erosive OLP may reflect higher circulating autoantibody levels. A study of 320 OLP patients showed that erosive OLP was the risk factor contributing to the detection of serum antinuclear antibody and anti-thyroglobulin antibody/anti-thyroid microsomal antibodies in patients with OLP.<sup>27</sup>

The present study has some limitations, such as a lack of serum cortisol measurements. It is recommended that more extensive study groups of OLP and control cases should be evaluated, with the same number of female and male participants within each group.

## CONCLUSIONS

Although the salivary cortisol level was relatively higher in patients with OLP, a significant association between salivary cortisol level and OLP was not observed. The flow rate of saliva was significantly lower in OLP. Further studies of structural changes of salivary gland in OLP are recommended.

## REFERENCES

- 1 Lehman JS, Tollefson MM, Gibson LE. Lichen planus. *Int J Dermatol*. 2009;48:682–694.
- 2 Chainani-Wu N, Silverman S, Lozada-Nur F, Mayer P, Watson JJ. Oral lichen planus: Patient profile, disease progression and treatment responses. *J Am Dent Assoc*. 2001;132:901–909.
- 3 Sklavounou-Andrikopoulou A, Chrysomali E, Iakovou M, Garinis G, Karameris A. Elevated serum levels of the apoptosis related molecules TNF- $\alpha$ , Fas/Apo-1 and Bcl-2 in oral lichen planus. *J Oral Pathol Med*. 2004;33:386–390.
- 4 DeRossi SS, Ciarrocca KN. Lichen planus, lichenoid drug reactions, and lichenoid mucositis. *Dent Clin North Am*. 2005;49:77–89.
- 5 Ismail SB, Kumar SK, Zain RB. Oral lichen planus and lichenoid reactions: Etiopathogenesis, diagnosis, management and malignant transformation. *J Oral Sci*. 2007;49:89–106.
- 6 Seoane J, Romero MA, Varela-Centelles P, Diz-Dios P, Garcia-Pola MJ. Oral lichen planus: A clinical and morphometric study of oral lesions in relation to clinical presentation. *Braz Dent J*. 2004;15:9–12.
- 7 Colquhoun AN, Ferguson MM. An association between oral lichen planus and a persistently dry mouth. *Oral Surg Oral Med Oral Pathol Oral Radiol Endod*. 2004;98:60–68.
- 8 Kho H-S, Chang J-Y, Kim Y-Y, Kim Y. MUC1 and toll-like receptor-2 expression in burning mouth syndrome and oral lichen planus. *Arch Oral Biol*. 2013;58:837–842.
- 9 Artico G, Freitas R, Santos Filho A, et al. Prevalence of *Candida* spp., xerostomia, and hyposalivation in oral lichen planus—A controlled study. *Oral Dis*. 2014;20:e36–e41.
- 10 Kraemer WJ, Ratamess NA. Hormonal responses and adaptations to resistance exercise and training. *Sports Med*. 2005;35:339–361.
- 11 Perogamvros I, Keevil B, Ray DW, Trainer PJ. Salivary cortisone is a potential biomarker for serum free cortisol. *J Clin Endocrinol Metab*. 2010;95:4951–4958.
- 12 Aardal E, Holm A-C. Cortisol in saliva-reference ranges and relation to cortisol in serum. *Clin Chem Lab Med*. 1995;33:927–932.
- 13 Girardi C, Luz C, Cherubini K, et al. Salivary cortisol and dehydroepiandrosterone (DHEA) levels, psychological factors in patients with oral lichen planus. *Arch Oral Biol*. 2011;56:864–868.
- 14 Ghalyani P, Tavangar A. Evaluation of anxiety and salivary cortisol level in patients with oral lichen planus. *J Islam Dent Assoc Iran*. 2010;22:23–29.
- 15 Shah B, Ashok L, Sujatha G. Evaluation of salivary cortisol and psychological factors in patients with oral lichen planus. *Indian J Dent Res*. 2009;20:288.
- 16 Koray M, Dülger O, Ak G, Horasanli S, Tanyeri H, Badur S. The evaluation of anxiety and salivary cortisol levels in patients with oral lichen planus. *Oral Dis*. 2003;9:298–301.
- 17 Carvalho PM, Castelo PM, Carpenter GH, Gavião MBD. Masticatory function, taste, and salivary flow in young healthy adults. *J Oral Sci*. 2016;58:391–399.
- 18 Lundstrom I, Goran K, Anneroth B, Bergstedt HF. Salivary gland function and changes in patients with oral lichen planus. *Eur J Oral Sci*. 1982;90:443–458.
- 19 Brand HS, Veerman E. Saliva and wound healing. *Chin J Dent Res*. 2013;16:7–12.
- 20 Kumagai K, Horikawa T, Gotoh A, et al. Up-regulation of EGF receptor and its ligands, AREG, EREG, and HB-EGF in oral lichen planus. *Oral Surg Oral Med Oral Pathol Oral Radiol Endod*. 2010;110:748–754.
- 21 Ivanovski K, Nakova M, Warburton G, et al. Psychological profile in oral lichen planus. *J Clin Periodontol*. 2005;32:1034–1040.
- 22 Payeras MR, Cherubini K, Figueiredo MA, Salum FG. Oral lichen planus: Focus on etiopathogenesis. *Arch Oral Biol*. 2013;58:1057–1069.
- 23 Turpeinen U, Hämäläinen E. Determination of cortisol in serum, saliva and urine. *Best Pract Res Clin Endocrinol Metab*. 2013;27:795–801.
- 24 Kaur B, Sunil M, Trivedi A, et al. Salivary cortisol as a diagnostic marker in oral lichen planus. *J Int Oral Health*. 2015;7:43.
- 25 Rödström PO, Jontell M, Hakeberg M, Berggren U, Lindstedt G. Erosive oral lichen planus and salivary cortisol. *J Oral Pathol Med*. 2001;30:257–263.
- 26 Neidhart M. Elevated serum prolactin or elevated prolactin/cortisol ratio are associated with autoimmune processes in systemic lupus erythematosus and other connective tissue diseases. *J Rheumatol*. 1996;23:476–481.
- 27 Chang JYF, Chiang CP, Hsiao CK, Sun A. Significantly higher frequencies of presence of serum autoantibodies in Chinese patients with oral lichen planus. *J Oral Pathol Med*. 2009;38:48–54.



## ORIGINAL CONTRIBUTION

# Retrospective Analysis of Pediatric Dermatologic Hospital Admissions

Martina Eva Leczycka, MD; Wioletta Baranska-Rybak, MD, PhD;  
Juliana Orrego Castellanos, BS; Roman Nowicki, MD, PhD

## ABSTRACT

Statistical data on the frequency of skin conditions in the Pomeranian region of Poland are limited in the field of pediatric dermatology, requiring a multidisciplinary approach to each patient. Dermatitis and skin allergies are the 10 most common pediatric conditions, with a prevalence of 20% among such chronic illnesses in developed countries. This analysis is limited to the recurrence of dermatologic diseases in the hospitalized pediatric population within the Pomeranian region for the purpose of future targeted education. Retrospective analysis included 282 participants over a 3-year period between 2013 and 2015, with admissions to the Department of Dermatology, Venereology, and Allergology at the Medical University of Gdansk. Diagnoses were obtained from the ward admission book and CliniNet database. (*SKINmed*. 2018;16:23–25)

The population for this study included 52% boys and 48% girls, the median age being 7 years old, with the youngest patient being 2 months old and oldest 17.9 years old. The most common hospitalizations included scabies (32%), atopic dermatitis (AD; 31%), psoriasis (12%), dermatitis, not specified (4.6%), dermatitis herpetiformis (3.9%), scleroderma (4.25%), and alopecia areata (2.48%). In 83% of cases, the children were hospitalized only once. The most common cause of recurrent admissions was AD; however, one patient presented with six admissions due to erythroderma, and one patient had five admissions due to mycosis fungoides. AD and scabies are the most common causes of admission to the dermatology department, and are a major concern for the pediatric dermatology population in the Pomeranian region of Poland.

Pediatric dermatology is a narrow field of medicine, often presenting a great challenge to dermatologists as well as pediatricians in the approach to treating patients. Up to 30% of pediatric primary care visits involve skin-related diseases.<sup>1</sup> It is common practice for children presenting with a skin eruption or pruritis to be seen initially by a pediatrician rather than a dermatologist. The importance of the dermatologic manifestations should, therefore, be stressed to pediatricians, as should a good level of communication across departments.

With growing body image pressure on teenagers from the media, skin conditions play a key role in self-worth and normal development.<sup>2</sup> Several centers report epidemiologic data for pediatric dermatologic manifestations. The geographic differences most often seen indicate the importance of localization and management. One study has reported AD, with an incidence of 25.9%, as the most common in its epidemiologic study, followed by pigmented nevi (9.1%) and verrucae (5.0%) for outpatient admissions.<sup>3</sup> In another study, AD was the most common disease, with a frequency of 59.5%, followed by 7.1% seborrheic dermatitis, and 4.2% superficial mycoses.<sup>4</sup> The Department of Dermatology, Venereology and Allergology of the Medical University of Gdansk is a specialized center admitting patients of all ages from the entire Pomeranian region. Patients who present with difficult diagnostic and therapeutic challenges are often referred by local pediatricians or other hospital departments.

## MATERIALS AND METHODS

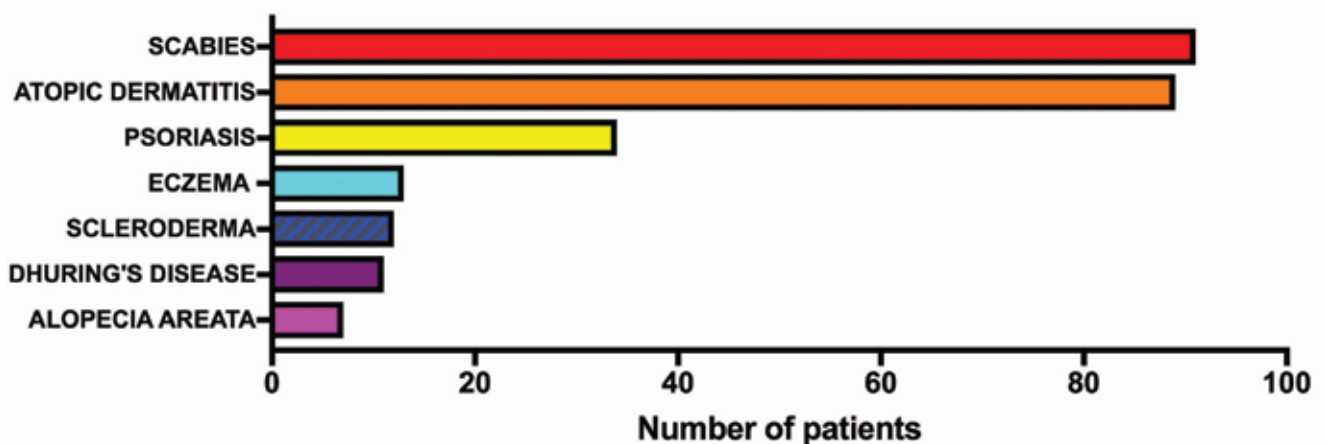
We retrospectively analyzed 282 pediatric patients admitted to the Department of Dermatology and Allergology of the Medical University of Gdansk over the 3-year period from January 2013 through December 2015.

From the Department of Dermatology, Venereology and Allergology, Medical University of Gdansk, Gdansk, Poland  
Address for Correspondence: Martina Eva Leczycka, Marsz. F. Focha 8/28, 80-156 Gdansk, Poland  
• Email: mleczycka7@gumed.edu.pl

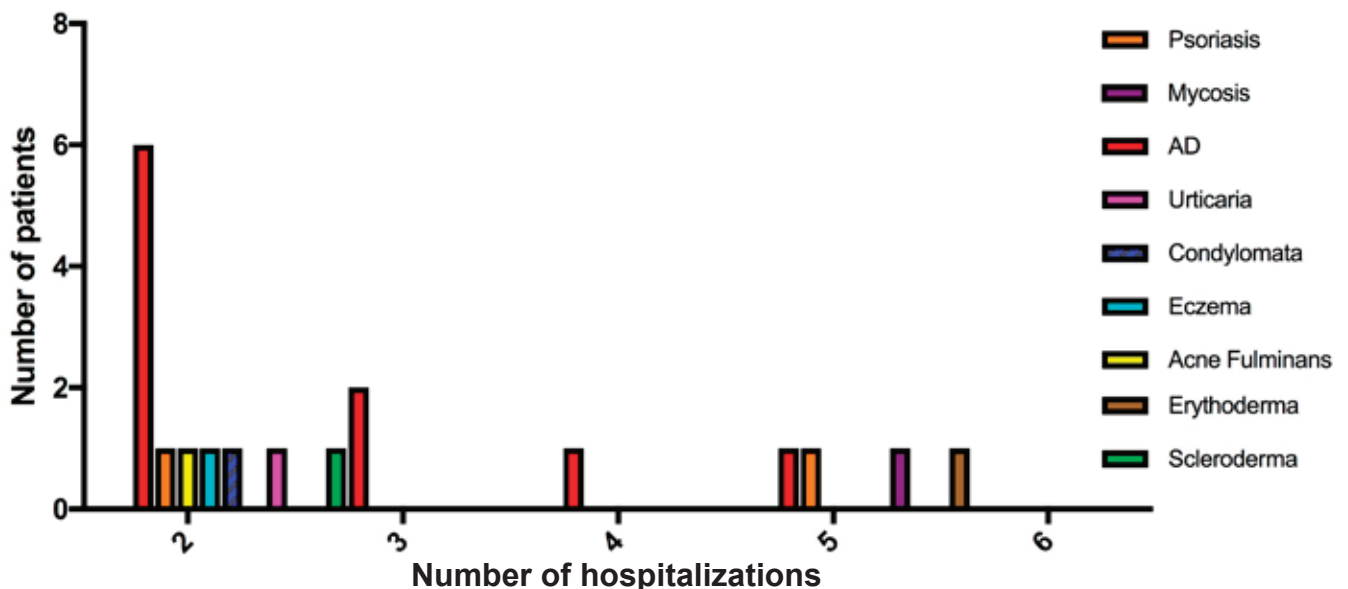
Personal identification number and initial diagnosis were collected by department nurses upon admission to the hospital and recorded in the admission book. Collected data were further compared with the patient's electronic records from the hospital electronic medical database—CliniNet. The age of the patients was deduced from the personal identification numbers. The final diagnosis determining our study was obtained from the CliniNet medical record database. The statistical data included patients aged from 2 months to 17 years 9 months, with a median age of 7 years old. We recorded the personal identification

number, number of hospitalizations, dates of hospitalizations, age at time of admission, final diagnosis, age of initial diagnosis, other associated conditions/past medical history, family history of atopy, mode of delivery, and APGAR score.

All data were obtained according to the Helsinki Declaration of 1975; the analysis was carried out ethically. Standard diagnostic criteria were used, and rare cases were also recorded, all in a confidential manner. Programs used to store and present the data were Numbers version 4.0.5 and GraphPad Prism 7.



**Figure 1.** Prevalence of the most common pediatric dermatologic hospital admissions over the 3-year study period, 2013 to 2015.



**Figure 2.** Frequency of multiple pediatric dermatologic hospital admissions according to etiology over the 3-year study period, 2013 to 2015. Abbreviation: AD, atopic dermatitis.

## RESULTS

Of the 282 participants, 52% were boys and 48% were girls. The median age was 7 years old, the youngest being 2 months old and oldest 17 years 9 months old. The most common hospital admissions included scabies (32%; mean age 7.24 years), AD (31%; mean age 7.0 years), psoriasis (12%), dermatitis, not specified (4.6%), dermatitis herpetiformis (3.9%), scleroderma (4.25%), alopecia areata (2.48%), and vasculitis (0.98%) (Figure 1). In 83% of cases, the children were hospitalized only on one occasion.

The importance of the causes of multiple hospitalizations was also noted (Figure 2). Despite scabies being the most common pediatric condition for readmission, readmission for AD is of more concern, with on average two visits to our department, implying the persistence of the disease and difficulty in treatment. We have also reported one patient with erythroderma which required six hospital admissions, and one patient with mycosis fungoides, admitted five times.

On further analysis of the yearly disease frequency, we found that AD predominated in 2013 and 2015, contrary to 2014, where an increase in scabies was observed. The number of psoriasis admissions increased consistently over the years, and we interestingly also discovered for 2015 a surprisingly higher number of cases of scleroderma, a condition that is exceptionally rare among the pediatric population.

Upon detailed investigation of the population with scabies, among the 91 subjects, 10 had associated AD in their past medical history records, 15 were also diagnosed with AD by our department at the time of hospitalization, and had patients had associated asthma. Asthma, chronic rhinitis, and AD fall into the atopy category—the tendency to hyperallergy and the production of immunoglobulin E due to genetic predisposition, resulting in 33% of cases of scabies being associated with atopy.

Of the patients with AD, 31% had two associated skin conditions—dermatitis herpetiformis and psoriasis—as the most frequent co-morbidities. Finally, in up to 7.9% of children admitted to the department with other skin manifestations, AD was also noted in their past medical history. Other diseases accompanying AD in the final diagnosis included predominantly asthma-associated upper respiratory tract infection in 15.7%.

## DISCUSSION

Establishing the right diagnosis is crucial to prevent adverse drug reactions and unfavorable clinical outcomes during a course of immunosuppressive treatment for scabies infections. Many pa-

tients in our clinical are hospitalized as a result of misdiagnosed nonlife-threatening disease and inappropriately applied treatment regimens.

The prevalence of childhood AD in the general European population approaches up to 20% in elementary school children.<sup>5</sup> The disruption of the antimicrobial barrier creates an ideal environment for the staphylococcal infections.<sup>6</sup> A hygiene hypothesis has been proposed, and a negative correlation between family size and AD has been revealed, in contrast to scabies infections in overcrowded settings such as nurseries and hospital wards.<sup>7</sup> One study highlights the importance of “crusted” scabies—the hyperproliferation of the mites causing scabies can lead to hyperkeratosis of the skin, which often is localized and evident in an immunocompromised patient—ie, after prolonged corticosteroid usage.<sup>8</sup> Several factors to consider are misdiagnosis, improper corticosteroid use, education on steroid stepdown protocols or inadequate patient education on a particular skin condition, and poor compliance with treatment.

## CONCLUSIONS

Corticosteroids, which seem to be the misleading first-line therapy when dermatologic manifestations are present, are often prescribed to scabies patients by primary doctors, and only worsen the prognosis. Adequate education should be provided by the primary doctor or by an outpatient pediatric dermatologist to reduce costs by decreasing the number of minor hospitalizations.

## REFERENCES

- 1 Prindaville B, Antaya RJ, Siegfried EC. Past, present, and future. *Pediatr Dermatol*. 2014;32:1–12.
- 2 Orion E, Wolf R. Psychologic consequences of facial dermatoses. *Clin Dermatol*. 2014;32:767–771.
- 3 Wenk C, Itin PH. Epidemiology of pediatric dermatology and allergology in the region of Aargau, Switzerland. *Pediatr Dermatol*. 2003;20:482–487.
- 4 Kakande B, Gumedze F, Hlela C, Khumalo NP. Focus on the top ten diagnoses could reduce pediatric dermatology referrals. *Pediatr Dermatol*. 2015;33:99–102.
- 5 Kay J, Gawkrödger DJ, Mortimer MJ, Jaron AG. The prevalence of childhood atopic eczema in a general population. *J Am Acad Dermatol*. 1994;30:35–39.
- 6 Eichenfield LF, Ellis CN, Mancini AJ, Paller AS, Simpson EL. Atopic dermatitis: Epidemiology and pathogenesis update. *Semin Cutan Med Surg*. 2012;31:S3–S5.
- 7 Thiers BH. Atopic dermatitis and the “hygiene hypothesis”: Too clean to be true? *Yearbook of Dermatology and Dermatologic Surgery*. 2006;2006:56–57.
- 8 Mounsey KE, McCarthy JS, Walton SF. Scratching the itch: new tools to advance understanding of scabies. *Trends Parasitol*. 2013;29:35–42.



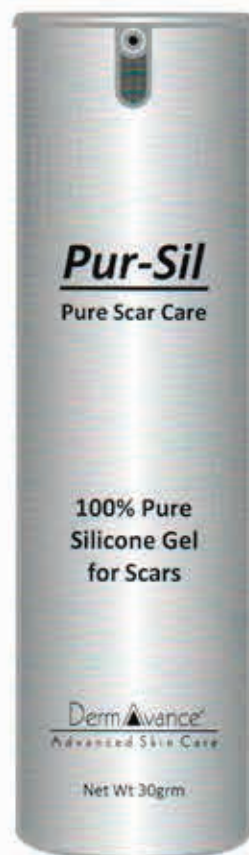**PHYSICIAN  
DISPENSED**

**PUR-SIL**  
PURE SCAR CARE

**THE 100% PURE SILICONE FOR  
SCAR THERAPY**



- Medical Grade Silicone
- Soft Silky Feel / Dries Instantly
- Post-Op and Post Laser Care



**DermAvance®**  
Advanced Skin Care

[www.DermAvance.com](http://www.DermAvance.com)

**Call Us Directly To Order (484) 568-0386**

## REVIEW

# Congenital Hypotrichosis and Congenital Atrichia

Najla A. Al-Dawsari, MD;<sup>1</sup> Feroze Kaliyadan, MD<sup>2</sup>

## ABSTRACT

A wide range of conditions can present with congenital hypotrichoses/atrichia. Awareness of these conditions can help in the proper and timely diagnosis and counseling of affected families, and in some cases avoid unnecessary investigations. The rapid growth in genetic analysis of diseases has also led to an increased knowledge of the genetic and molecular basis of many of these conditions. This contribution briefly reviews updates on some of the most common conditions associated with congenital hypotrichosis/atrichia. (*SKINmed*. 2018;16:27–32)

**A**ny kind of hypotrichosis or atrichia developing in a young couple's infant can be a major source of psychological stress for the family as a whole. For the dermatologist, it is important to be aware of the wide variety of conditions that can be associated with congenital hypotrichosis or atrichia. There have been many different attempts to classify congenital hypotrichosis. One of the most accepted and practical follows the classification of congenital alopecia and hypotrichosis proposed by Camacho.<sup>1</sup> The Camacho classification broadly divides congenital alopecia and hypotrichosis into generalized and localized hypotrichosis. Recent developments in the field of genetics, especially whole-exome and whole-genome sequencing, have led also led to a better understanding of genetic hypotrichosis.<sup>2</sup>

## TERMINOLOGY

Unlike alopecia, which describes hair loss in a previously hairy area, the term congenital hypotrichosis refers to the absence of hair growth in the first place. Most described cases of hypotrichoses are associated with genetic defects, many of which have now been pinpointed. Congenital atrichia (also called papular atrichia) is associated with the presence of normal hair at birth, which is gradually lost during the course of childhood and never regrows. Congenital atrichia is also considered to be essentially a genetic defect, which leads to a breakdown in communication between the dermal papilla and the hair.<sup>3–5</sup>

## CONGENITAL ATRICHIA

Atrichia congenita with papular lesions (APL) is a group of genetic conditions characterized clinically by complete and irre-

versible hair loss shortly after birth. APL is associated with the development of keratin-filled cysts, giving the papular appearance. The disease has been reported in Indian, Irish, and Arab Israeli populations. Inheritance is usually autosomal recessive, although sporadic, dominant, and irregular dominant inheritance have been reported.

The exact etiology is not known, but homozygous mutations in the 'hairless' gene (*HR*) have been suggested to be one of the possible factors involved. *HR* genes are located on chromosome 8p21.2 and encode a putative single zinc finger transcription factor protein, which is important in regulating the normal hair cycle. The mutation diminishes DNA-binding activity, disturbing hair cycle events.<sup>5–7</sup> The hair matrix cells in APL undergo premature apoptosis and separation from the epithelial sheath. Communication between the dermal papillae and stem cells in the bulge are not transmitted, leading to cessation of hair growth.

It is important to differentiate conditions like APL from early-onset alopecia universalis, and useful diagnostic criteria for APL have been proposed.<sup>4</sup> These include five major criteria (of which four are required for diagnosis) and five supplementary criteria. The major criteria are: permanent and complete absence of scalp hair by the first few months of life; few to widespread, smooth, whitish, or milia-like papules on the face, scalp, arms, elbows, thighs, or knees from infancy or childhood; replacement of mature follicle structures by follicular cysts filled with cornified material on scalp histology; mutations in the *HR* gene; and clinical and or molecular exclusion of vitamin D–dependent rickets (as mutations in the vitamin D receptor gene associated with rickets have been found to produce a phenotypical picture similar to

From Johns Hopkins Aramco Healthcare, Dhahran,<sup>1</sup> and the Department of Dermatology, College of Medicine, King Faisal University, Hofuf,<sup>2</sup> Saudi Arabia

Address for Correspondence: Najla A. Al-Dawsari, Johns Hopkins Aramco Healthcare, PO Box 2121, Dhahran 31311, Saudi Arabia • E-mail: Najla.aldawsari@gmail.com

the atrichia associated with *HR* gene mutations<sup>8</sup>). The minor criteria are: family history of consanguinity; absence of secondary axillary, pubic, or body hair growth and/or sparse eyebrows and eyelashes; normal growth and development, including normal bones, teeth, nails, and sweating; whitish hypopigmented streaks on the scalp; and lack of response to any treatment modality.<sup>4</sup>

Dermatoscopy of the scalp (trichoscopy) might be another useful tool for diagnosing APL and differentiating it from alopecia universalis. Dermatoscopy of completely developed APL will show absent follicular orifices, without features such as black/yellow dots and exclamation mark hairs, which can be seen in variants of alopecia areata.<sup>9</sup>

## CONGENITAL HYOPTRICHOSIS

### GENERALIZED TYPES

The Table summarizes types of congenital hypotrichosis.

#### *Hereditary hypotrichosis simplex of the scalp*

This rare autosomal dominant genotrichosis is caused by mutations in the *CDSN* gene encoding corneodesmosin. *CDSN* codes for a keratinocyte adhesion molecule expressed in the inner root sheaths of hair follicles and has been found to be physiologically important for hair follicle function. The mutation causes expression of an abnormal protein that might be toxic to hair growth. The disease has been reported in Chinese, Indian, and Mexican families.

The hairs are normal in the first years of life, after which patients develop progressive, gradual loss of scalp hair that starts in the middle of the first decade of life and progresses to almost complete baldness by the third decade. Body hairs are spared. Scalp biopsies usually show a decreased number of hair follicles with faint chronic, predominantly lymphocytic perifollicular infiltration or lack of inflammation. Electron microscopy and light microscopy usually do not show any abnormalities.<sup>10–13</sup>

#### *Hereditary hypotrichosis simplex*

This is a rare autosomal dominant form of hair loss characterized by hair follicle miniaturization. It is caused by mutations in the *APCDD1* gene, encoding adenomatous polyposis coli down-regulated 1, which is expressed in the epidermal and dermal compartments of the hair follicle, and has a role in hair follicle miniaturization. *APCDD* is expressed in the human scalp. The disease has been reported in Italian, Chinese, and Pakistani families.

Hairs are normal or sparse at birth and then start to thin and grow only slowly, leaving the patient with short body and scalp

hair. Eyelashes, eyebrows, and male beards are usually spared. Occasionally, hairs are light-colored with a hypopigmented hair shaft and a tapered end. There are no other systemic anomalies. Under light microscopy, the bulb portion of the plucked hairs may show dystrophic features and evidence of miniaturization.<sup>14,15</sup>

#### *Autosomal recessive hypotrichosis with wooly hair*

This autosomal recessive disorder is described in consanguineous Pakistani families. The disease is caused by mutations in either the *LIPH* gene, encoding lipase H, or the *LPAR6* gene, encoding lysophosphatidic acid receptor 6; these are expressed in the inner root sheath of the hair follicle and are important in hair follicle growth and differentiation. Patients present with hypotrichosis or complete loss of scalp hair, along with wooly hair. Eyelashes and body hairs are reported to be sparse in some cases, and there sparing of the beard hairs in males.<sup>16,17</sup>

#### *Localized autosomal recessive hypotrichosis or autosomal recessive hypotrichosis simplex*

With this group of autosomal recessive disorders, patients have fragile scalp, sometimes trunk, and extremity hairs that break easily, leaving sparse, short hairs. Facial, axillary, and pubic hair are usually spared. Occasionally, patients complain of scalp pruritus.

These hair changes are described with three different mutations. Desmoglein 4 is a member of the desmosomal cadherin family that is expressed in the hair follicle and suprabasal epidermis; it is important in hair follicle proliferation and differentiation. Mutation of the *DSG4* gene has been reported in a group of Pakistani and Iraqi/Iranian families.<sup>18–20</sup> Mutation in either the *LIPH* or the *LPAR6* gene can cause similar features in the absence of wooly hair (as the mutation is at a different locus). Electron and light microscopic features are variable between patients, and include thick and thin hair parts on light microscopy, and longitudinal grooving with absent cuticular cells on electron microscopy.<sup>20,21</sup>

#### *Marie Unna hereditary hypotrichosis*

This is an autosomal dominant disorder caused by a mutation in the untranslated region of the *HR* gene. This region is an upstream regulator of the *HR* gene located on chromosome 8p21.<sup>22–24</sup> The disease has been described in Europe, North America, India, and China.

Hypotrichosis is distinctive at each stage of life of affected individuals. At birth, affected individuals have absent hair followed by regrowth of coarse, twisted, wiry hair (a diagnostic clue) in childhood, and then progressive nonscarring loss of hair on pu-

**Table II. Total Number of Patients Examined for Midline Capillary Formation Nuchae and Estimated Prevalence by Age Group in the Present and 19 Additional Studies**

SYNDROME	MODE OF INHERITANCE	GENE INVOLVED	HAIR ABNORMALITIES	ASSOCIATED FEATURES	HISTOPATHOLOGY	LIGHT MICROSCOPY	ELECTRON MICROSCOPY
Hereditary hypotrichosis simplex of the scalp	AD	<i>CDSV</i>	Hairs normal in the first years of life Progressive loss of scalp hair starting in the middle of the first decade of life Almost complete loss of scalp hair by the third decade Body hairs spared	None	Decreased number of hair follicles with faint chronic, predominantly lymphocytic perifollicular infiltration or no inflammation	Normal	
Hereditary hypotrichosis simplex	AD	<i>APCDD1</i>	Normal or sparse scalp hairs at birth Thinning and slow growth leaving the patient with short scalp and body hairs Eyelashes, eyebrows, and male beards are usually spared ± Light-colored hairs and tapered shafts	None		Dystrophic features and evidence of miniaturization involving hair bulb	
Autosomal recessive hypotrichosis with woolly hair	AR	<i>LIPH</i> or <i>LPAR6</i>	Hypotrichosis or complete loss of scalp hair with woolly hair Eyelashes and body hairs sparse in some cases, with sparing of beard hairs in males	None			
Localized autosomal recessive hypotrichosis or autosomal recessive hypotrichosis simplex	AR	<i>DSG4</i> <i>LIPH</i> <i>LPAR6</i>	Fragile scalp hairs, sometimes trunk and extremity hairs Sparse short hairs Facial, axillary, and pubic hair usually spared Scalp pruritus			Thick and thin hair parts	Longitudinal grooving with absent cuticular cells
Marie-Unna hereditary hypotrichosis	AD	Untranslated region of HR	Absent hair at birth followed by regrowth of coarse, twisted, wiry hair, followed by progressive nonscarring loss on puberty Body hairs including eyebrows and eyelashes are sparse or absent	Rare Milia-like facial lesions, tooth abnormalities, limb abnormalities, Ehlers-Danlos syndrome, and juvenile macular degeneration	Mild to moderate inflammatory infiltrate with reduced number of hair follicles and lack of scarring	Hair shafts deeply pigmented with variations in hair shaft diameter, and irregularly twisted hairs	Peeling of the cuticle occasionally seen
Hypotrichosis with juvenile macular dystrophy	AR	<i>CDH3</i>	Short and sparse scalp hair	Progressive macular dystrophy	Increased catagen-reagen hair follicles Increased ratio of vellus hair follicles to terminal hair follicles Lack of inflammation or scarring		

*Continued*

**Table II. Total Number of Patients Examined for Midline Capillary Formation Nuchae and Estimated Prevalence by Age Group in the Present and 19 Additional Studies (Continued)**

SYNDROME	MODE OF INHERITANCE	GENE INVOLVED	HAIR ABNORMALITIES	ASSOCIATED FEATURES	HISTOPATHOLOGY	LIGHT MICROSCOPY	ELECTRON MICROSCOPY
Ectodermal dysplasia, ectrodactyly, and macular dystrophy	AR	<i>CDH3</i>	Short and sparse scalp hair	Progressive macular dystrophy Ectodermal defects Limb defects	Absence of mature hair follicles, lack of hair shafts, and inflammation Hair follicles are replaced by follicular cysts filled with cornified material		
Atrichia congenita (atrachia with papular lesions)	AR Sporadic AD Irregular dominant	<i>HR</i>	Shedding of all scalp hairs between 1 and 6 months of age Eyebrow, eyelash, pubic, axillary hairs, and body hairs may be sparse or absent	Whitish hypopigmented streaks on the scalp Milia-like papules may be seen on the scalp, face, arms, elbows, thighs, or knees			

AD, autosomal dominant; AR, autosomal recessive.

berty that clinically mimics androgenic alopecia. Body hairs including eyebrows and eyelashes are sparse or absent. Other rare associated features include milia-like facial lesions, tooth abnormalities, limbs abnormalities, Ehlers-Danlos syndrome, and juvenile macular degeneration.

On light microscopy, the hair shafts are deeply pigmented and of varying diameter, with irregularly twisted hairs. Longitudinal grooves, focal trichoschisis, and peeling of the cuticle can occasionally be seen on electron microscopy, but are not pathognomonic of the condition. On histopathology, there is a mild to moderate inflammatory infiltrate with a reduced number of hair follicles and lack of scarring.<sup>25–27</sup>

### *Marii hypotrichosis*

This autosomal recessive disorder is described in the Mari population, a Finno-Ugric ethnic group who have traditionally lived along the Volga and Kama rivers of Russia. Patients present with hypotrichosis of scalp hair after birth, and any hairs left are usually wiry and twisted. Eyebrows and eyelashes are gradually lost within the first year of life. Pubic and axillary hairs are absent, and other body hairs are thin and sparse. Rarely, patients present with follicular hyperkeratosis.<sup>28,29</sup>

The disease is attributed to a mutation in the *LIPH* gene, expressed in hair follicles. This gene encodes membrane-associated phosphatidic acid–selective phospholipase A1 $\alpha$ , which is important in regulating the production of bioactive lipids important in hair growth and development.<sup>30</sup>

### *Hypotrichosis with juvenile macular dystrophy*

This autosomal recessive disorder is described in Muslim Arab Israeli populations and some Portuguese families. It is caused by loss-of-function mutations in *CDH3*, which encodes P-cadherin, a component of the adherent junction in the retinal pigment epithelium and hair follicles; it is also important in regulating cell signaling, cycling, and growth in the hair follicles. Hair abnormalities include short and sparse scalp hair along with progressive macular dystrophy leading to blindness. Increased catagen-telogen hair follicles, an increased ratio of vellus hair follicles to terminal hair follicles, and lack of inflammation or scarring may be observed on histopathology.<sup>31–33</sup> Ectodermal dysplasia, ectrodactyly, and macular dystrophy syndrome are caused by the same mutation.<sup>34</sup>

### *Cartilage-hair hypoplasia*

This is an autosomal recessive disorder caused by a mutation in the *RMRP* gene, encoding RNA component of mitochondrial



RNA processing endoribonuclease, which is involved in ribosomal assembly and cell cycle regulation.<sup>35</sup> The disease is common in the Amish community in the United States. It has been also reported in Indian, Finnish, and Japanese populations.<sup>36–38</sup>

Patients usually have short stature and short limbs, along with joint laxity and mobility issues. In most cases, affected patients have immunodeficiency and increased risk of malignancy (non-Hodgkin lymphoma, basal cell carcinoma). Other associated clinical manifestations are anemia, defective spermatogenesis, and gastrointestinal abnormalities. The scalp shows sparse thin hairs with blonde eyebrows and eyelashes. Hair shafts lack a central pigment core.<sup>39–41</sup>

### LOCALIZED TYPES

The localized types of congenital hypotrichosis are relatively easier to diagnosis. The most common include the following.

#### ***Congenital triangular alopecia (Brauer nevus)***

Congenital triangular alopecia is a usually unilateral patch of alopecia in the frontotemporal region. It is a nonprogressive disorder presenting as a triangular, oval, or lancet-shaped patch of alopecia in the frontotemporal area, and can be present at birth or develop later in life.

The exact etiology is unclear. It has been attributed to an underlying mosaicism, and may be inherited as a paradominant trait in which a postzygotic loss of the wild-type allele in a heterozygote state leads to disease. Others have suggested that congenital triangular alopecia may result from an ectodermal defect and should be included in the group of epidermal nevi. Associations with Down syndrome and phakomatosis pigmentovascularis have been reported. The diagnosis is easily made by the typical pattern. Histologically, the hair follicles are seen to be miniaturized. Medical treatment is not effective, but follicular unit hair transplantation has been tried effectively in some cases.<sup>42</sup>

#### ***Aplasia cutis congenita (Adams-Oliver syndrome and other associations)***

Aplasia cutis congenita is a part of heterogeneous group of disorders characterized by the absence of a portion of skin in a localized or widespread area of the scalp at birth. Adams-Oliver syndrome is characterized by aplasia cutis congenita of the scalp and terminal transverse limb defects. Aplasia cutis congenita lesions usually occur in the midline of the parietal or occipital region. Additional major features frequently include cardiovascular malformations/dysfunction (23%), brain anomalies, and, less frequently renal, liver, and eye anomalies.<sup>43</sup>

Other conditions associated with localized hypotrichosis include nevoid conditions such as nevus sebaceous.<sup>3</sup>

### CONCLUSIONS

Congenital atrichia and hypotrichia are relatively rare conditions. APL is the most common presentation of congenital atrichia, while congenital hypotrichia includes a group of conditions, broadly classified into localized and generalized types. Advances in genetic studies have led to an improved understanding of the pathogenesis of conditions characterized by congenital hypotrichosis and congenital atrichia. Further research is warranted to explore treatment options based on the molecular basis of these conditions.

### REFERENCES

- 1 Camacho F. Genodermatosis with hypotrichosis. In: Camacho F, Montagna W, eds. *Tricology*. Madrid: Aula Médica, 1996:219–236.
- 2 Ramot Y, Zlotogorski A. Molecular genetics of alopecias. *Curr Probl Dermatol*. 2015;47:87–96.
- 3 Bennàssar A1, Ferrando J, Grimalt R. Congenital atrichia and hypotrichosis. *World J Pediatr*. 2011;7:111–117.
- 4 Zlotogorski A, Panteleyev AA, Aita VM, Christiano AM. Clinical and molecular diagnostic criteria of congenital atrichia with papular lesions. *J Invest Dermatol*. 2002;118:887–890.
- 5 Thomas M, Daniel S. Atrichia congenita with papular lesions. *Indian J Dermatol Venereol Leprol*. 2011;77:70–72.
- 6 Sprecher E, Lestringant GG, Szargel R, et al. Atrichia with papular lesions resulting from a nonsense mutation within the human hairless gene. *J Invest Dermatol*. 1999; 113:687–690.
- 7 Indelman M, Bergman R, Lestringant GG, Peer G, Sprecher E. Compound heterozygosity for mutations in the hairless gene causes atrichia with papular lesions. *Br J Dermatol*. 2003;148:553–557.
- 8 Miller J, Djabali K, Chen T, et al. Atrichia caused by mutations in the vitamin D receptor gene is a phenocopy of generalized atrichia caused by mutations in the hairless gene. *J Invest Dermatol*. 2001;117:612–617.
- 9 Pedrosa A, Nogueira A, Morais P, et al. Photoletter to the editor: Congenital atrichia associated with an uncommon mutation of HR gene. *J Dermatol Case Rep*. 2013;7:18–19.
- 10 Levy-Nissenbaum E, Betz RC, Frydman M, et al. Hypotrichosis simplex of the scalp is associated with nonsense mutations in CDSN encoding corneodesmosin. *Nat Genet*. 2003;34:151–153.
- 11 Dávalos NO, García-Vargas A, Pforr J, et al. A non-sense mutation in the corneodesmosin gene in a Mexican family with hypotrichosis simplex of the scalp. *Br J Dermatol*. 2005;153:1216–1219.
- 12 Moravvej-Farshi H, Ayatollahi A, Hejazi S. Hereditary hypotrichosis simplex of the scalp. *Indian J Dermatol*. 2014;59:634.

- 13 Yang SX, Yin JH, Lin ZM, et al. A novel nonsense mutation in the CDSN gene underlying hypotrichosis simplex of the scalp in a Chinese family. *Clin Exp Dermatol*. 201;39:75–77.
- 14 Shimomura Y, Agalliu D, Vonica A, et al. APCDD1 is a novel Wnt inhibitor mutated in hereditary hypotrichosis simplex. *Nature*. 2010;464:1043–1047.
- 15 Baumer A, Belli S, Trüeb RM, Schinzel A. An autosomal dominant form of hereditary hypotrichosis simplex maps to 18p11.32-p11.23 in an Italian family. *Eur J Hum Genet*. 2000;8:443–448.
- 16 Tariq M, Azhar A, Baig SM, Dahl N, Klar J. A novel mutation in the lipase H gene underlies autosomal recessive hypotrichosis and woolly hair. *Sci Rep*. 2012; 2:730.
- 17 Khan S, Habib R, Mir H, et al. Mutations in the LPAR6 and LIPH genes underlie autosomal recessive hypotrichosis/woolly hair in 17 consanguineous families from Pakistan. *Clin Exp Dermatol*. 2011;36:652–654.
- 18 John P, Tariq M, Arshad Rafiq M, et al. Recurrent intragenic deletion mutation in desmoglein 4 gene underlies autosomal recessive hypotrichosis in two Pakistani families of Balochi and Sindhi origins. *Arch Dermatol Res*. 2006;298:135–137.
- 19 Bazzi H, Martinez-Mir A, Kljuic A, Christiano AM. Desmoglein 4 mutations underlie localized autosomal recessive hypotrichosis in humans, mice, and rats. *J Investig Dermatol Symp Proc*. 2005;10:222–224.
- 20 Suga H, Tsunemi Y, Sugaya M, et al. Hair shaft abnormalities in localized autosomal recessive hypotrichosis 2 and a review of other non-syndromic human alopecias. *Acta Derm Venereol*. 2011;91:486–488.
- 21 Tariq M, Ayub M, Jelani M, et al. Mutations in the P2RY5 gene underlie autosomal recessive hypotrichosis in 13 Pakistani families. *Br J Dermatol*. 2009;160:1006–1010.
- 22 Yang J, Liang Y, Zeng K, Huang L, Zheng M. Marie Unna hereditary hypotrichosis: A recurrent c.74C>T mutation in the U2HR gene and literature review. *Int J Dermatol*. 2014;53:206–209.
- 23 Wen Y, Liu Y, Xu Y, et al. Loss-of-function mutations of an inhibitory upstream ORF in the human hairless transcript cause Marie Unna hereditary hypotrichosis. *Nat Genet*. 2009;41:228–233.
- 24 Yang S, Gao M, Cui Y, et al. Identification of a novel locus for Marie Unna hereditary hypotrichosis to a 17.5 cM interval at 1p21.1-1q21.3. *J Invest Dermatol*. 2005;125:711–714.
- 25 Srinivas SM, Hiremagalore R. Marie-unna hereditary hypotrichosis. *Int J Trichology*. 2014;6:182–184.
- 26 Podjasek JO, Hand JL. Marie-Unna hereditary hypotrichosis: Case report and review of the literature. *Pediatr Dermatol*. 2011;28:202–204.
- 27 Farkas K, Nagy N, Kinyó A, Kemény L, Széll M. A newly identified missense mutation of the HR gene is associated with a novel, unusual phenotype of Marie Unna hereditary hypotrichosis 1 including limb deformities. *Arch Dermatol Res*. 2012;304:679–681.
- 28 Ginter EK, Mamedova RA, Kozlova SI, et al. [Diversity of hereditary pathology in the population of Marii El Republic and its differentiation with respect to gene frequencies for hereditary diseases] [in Russian]. *Genetika*. 1998;34:963–972.
- 29 Rogaev EI, Zinchenko RA, Dvoryachikov G, Sherbatich T, Ginter EK. Total hypotrichosis: Genetic form of alopecia not linked to hairless gene. *Lancet*. 1999;354:1097–1098.
- 30 Kazantseva A, Goltsov A, Zinchenko R, et al. Human hair growth deficiency is linked to a genetic defect in the phospholipase gene LIPH. *Science*. 2006;314:982–985.
- 31 Shimomura Y, Wajid M, Kurban M, Christiano AM. Splice site mutations in the P-cadherin gene underlie hypotrichosis with juvenile macular dystrophy. *Dermatology*. 2010;220:208–212.
- 32 Samuelov L, Sprecher E, Paus R. The role of P-cadherin in skin biology and skin pathology: Lessons from the hair follicle. *Cell Tissue Res*. 2015;360:761–771.
- 33 Bergman R, Sapir M, Sprecher E. Histopathology of hypotrichosis with juvenile macular dystrophy. *Am J Dermatopathol*. 2004;26:205–209.
- 34 Kjaer KW, Hansen L, Schwabe GC, et al. Distinct CDH3 mutations cause ectodermal dysplasia, ectrodactyly, macular dystrophy (EEM syndrome). *J Med Genet*. 2005;42:292–298.
- 35 Cherkaoui Jaouad I, Laarabi FZ, Chafai Elalaoui S, et al. Novel mutation and structural RNA analysis of the non-coding RNase MRP gene in cartilage-hair hypoplasia. *Mol Syndromol*. 2015;6:77–82.
- 36 Nakashima E, Mabuchi A, Kashimada K, et al. RMRP mutations in Japanese patients with cartilage-hair hypoplasia. *Am J Med Genet A*. 2003;123A:253–256.
- 37 Shiasi Arani K. Cartilage hair hypoplasia: First report from Iran. *Med J Islam Repub Iran*. 2013;27:157–160.
- 38 Narayanan DL, Shukla A, Siddesh AR, et al. Cartilage hair hypoplasia: Two unrelated cases with g.70 A > G mutation in RMRP gene. *Indian J Pediatr*. 2016;83:1003–1005.
- 39 Riley P, Jr, Weiner DS, Leighley B, et al. Cartilage hair hypoplasia: Characteristics and orthopaedic manifestations. *J Child Orthop*. 2015;9:145–152.
- 40 Ip W, Gaspar HB, Kleta R, et al. Variable phenotype of severe immunodeficiencies associated with RMRP gene mutations. *J Clin Immunol*. 2015;35:147–157.
- 41 Fenollar-Cortés M, Lara-Orejas E, González-Meneses A, Ruibal-Francisco JL, Trujillo-Tiebas MJ. [Clinical and molecular diagnostics of a cartilage-hair hypoplasia: Two new cases] [in Spanish]. *An Pediatr (Barc)*. 2015;82:436–439.
- 42 Yin Li VC, Yesudian PD. Congenital triangular alopecia. *Int J Trichology*. 2015;7:48–53.
- 43 Lehman A, Wuyts W, Patel MS. Adams-Oliver syndrome. In: Pagon RA, Adam MP, Ardinger HH, et al, eds. *GeneReviews*® [Internet]. Seattle (WA): University of Washington, Seattle; 1993–2016. 2016 Apr 14.

## SELF ASSESSMENT EXAMINATION

W. Clark Lambert, MD, PhD

*Instructions for questions 1–5: For each numbered question, choose the one best numbered response, unless directed otherwise.*

1. Congenital hypotrichosis is distinguished from alopecia by:
  - a. Hair loss in a previously hairy area.
  - b. Absence of hair growth in the first place.
  - c. Dense, curly hair instead of normal hair.
  - d. Any of the above.
  - e. None of these.
2. Alopecia is distinguished from congenital hypotrichosis by:
  - a. Hair loss in a previously hairy area.
  - b. Absence of hair growth in the first place.
  - c. Dense, curly hair instead of normal hair.
  - d. Any of the above.
  - e. None of these.
3. Most described cases of hypotrichosis are associated with:
  - a. Genetic defect(s).
  - b. Metabolic defect(s) due to malnutrition.
  - c. Metabolic defect(s) due to zinc deficiency.
  - d. Metabolic defect(s) due to radiation in the environment.
  - e. Metabolic defect(s) due to unknown causes.
4. Disorders sometimes associated with one or more of the various types of generalized hypotrichosis or atrichia include:
  - a. Ehlers-Danlos syndrome.
  - b. Juvenile macular degeneration of the eye.
  - c. Limb abnormalities.
  - d. Milia-like facial lesions.
  - e. Tooth abnormalities.
  - f. All of the above.
5. Which one of the following is most prone to mimic congenital atrichia (atrichia congenita with papular lesions, or APL)?
  - a. Vitamin A deficiency.
  - b. Vitamin C deficiency.
  - c. Vitamin D deficiency.
  - d. Vitamin E deficiency.
  - e. Vitamin K deficiency.

**ANSWERS TO EXAMINATION:**  
 1. b; 2. a; 3. a; 4. f; 5. c.



From the Departments of Pathology and Dermatology, Rutgers University – New Jersey Medical School, Newark, NJ  
 Address for Correspondence: W. Clark Lambert, MD, PhD, Room H576 Medical Science Building, Rutgers University – New Jersey Medical School, 185 South Orange Avenue, Newark, NJ 07103 • E-mail: [lamberwc@njms.rutgers.edu](mailto:lamberwc@njms.rutgers.edu)

# Edward L. Keyes Resident Contest for Outstanding Case Reports

*13th World Congress of the International Academy of Cosmetic Dermatology*

*Dubrovnik, Croatia June 28–July 1, 2018*

*Abstract deadline: March 31, 2018*

To be awarded for the best Case Report submitted by a physician in training (resident, fellow, or registrar) for presentation at the 13th World Congress of the International Academy of Cosmetic Dermatology in Dubrovnik, Croatia from June 28–July 1, 2018.

We invite you to submit original Case Reports that reflect the presentation of new ideas and original observations to the Academy membership and other attendees of the Congress. The case may be medical, surgical, and cosmetic (or combined) in nature.

The author whose abstract obtains the highest score during the review process will receive a scholarship by the IACD to present the full paper at the 13th World Congress of the International Academy of Cosmetic Dermatology in Dubrovnik, Croatia from June 28–July 1, 2018. The scholarship will provide reasonable travel expenses, lodging for 3 nights, the Congress registration fee, and a basic spending stipend.

Please submit your case report abstract via email to [vrosic@medicine.bsd.uchicago.edu](mailto:vrosic@medicine.bsd.uchicago.edu) before noon, CDT, March 31, 2018. The abstract should be no longer than 2,500 characters including spacing. Material that was previously presented, published, or submitted for publication should not be offered. Applications will be graded based upon the educational value of the abstract and the extent to which it presents new and significant work. The Review Committee strongly recommends that abstracts have an organized, coherent, well-thought-out, and complete presentation. Please note that no paper submitted for consideration will be eligible if it has already been, or is in consideration for, publication elsewhere at any time prior to the meeting. The winner(s) agree to publish their outstanding case report(s) in *SKINmed: Dermatology for the Clinician*, an official publication of the International Academy of Cosmetic Dermatology. By submitting your paper for consideration, you give *SKINmed: Dermatology for the Clinician* first-rights of refusal for publication through December 31, 2018.

The applicant must be in training at the time of the Congress presentation.

All applicants will receive e-mail notice of the Resident Case Report Review Committee's decision by May 1, 2018.



Vesna Petronic-Rosic, MD, MSc  
Chair, Resident Contest Committee  
Professor and Chief

The University of Chicago Pritzker School of Medicine  
Section of Dermatology

Tel: +1.773.702.6559

[vrosic@medicine.bsd.uchicago.edu](mailto:vrosic@medicine.bsd.uchicago.edu)

## NEW THERAPY UPDATE

*William Abramovits, MD; Aditya K. Gupta, MD, PhD, FRCPC, Section Editors***Odomzo<sup>®</sup> (Sonidegib)**Aditya K. Gupta, MD, PhD, FRCPC;<sup>1,2</sup> Rachel R. Mays, BSc;<sup>2</sup>  
William Abramovits, MD;<sup>3,4,5,6</sup> Kimberly Dawn Vincent, MD<sup>7</sup>

**B**asal cell carcinoma (BCC), a subtype of nonmelanoma skin cancer, is the most frequently occurring form of skin cancer in the United States and Canada.<sup>1,2</sup> Although it seldom results in death or metastatic disease, BCC can cause significant morbidity due to its destructive local spread.<sup>3</sup> The global prevalence of BCC is increasing,<sup>4</sup> BCC initially affects the epidermis and later invades deeper tissues. Standard first-line treatment of BCC usually involves local sites, but still, there are cases of BCC that cannot be appropriately treated with such modalities, including recurrences after conventional therapy; therefore other forms of treatment must be considered.<sup>5</sup> Sonidegib (Odomzo<sup>®</sup>, formerly LDE225; Novartis, Basel, Switzerland) is an oral, bioavailable small molecule that acts on the smoothed (Smo) receptor antagonist. It was approved in July 2015 by the US Food and Drug Administration for the treatment of locally advanced recurrent BCC (laBCC).<sup>6</sup> Clinical trials have shown sonidegib to be effective and safe for the treatment of laBCC.<sup>7-12</sup> Vismodegib (Erivedge<sup>™</sup>; Roche, Basel, Switzerland), a treatment for metastatic BCC (mBCC) and laBCC, was approved by the Food and Drug Administration in 2012.<sup>13</sup>

**MECHANISM OF ACTION**

The sonic hedgehog (Hh) signaling pathway transmits information to embryonic cells that is required for proper cell differentiation, proliferation, and tissue patterning. Smo is an Hh signal transducer structurally similar to G protein-coupled receptors; it relies on heterotrimeric G proteins to effectively transduce the Hh signal. Sonidegib works by blocking this transduction.

**PHASE I CLINICAL DATA**

The first phase I trial investigated the maximum tolerated dose and dose-limiting toxicities of oral sonidegib in 103 patients with various forms of advanced solid tumors.<sup>8</sup> Dosages ranged from 100 to 3000 mg daily and 250 to 750 mg twice daily in 28-day cycles. If patients tolerated the assigned dose for at least two cycles, dose escalation was allowed. Before the first cycle, there was a single-dose 7-day pharmacokinetic run-in period to describe the pharmacokinetic profile. The maximum tolerated doses reported were 800 mg daily and 250 mg twice daily. The most frequent dose-limiting toxicity was reversible grade 3 or 4 elevated serum creatine kinase, experienced by 18% of patients at doses  $\geq 800$  mg daily or  $\geq 250$  mg twice daily. Six of the 16 (37.5%) patients with laBCC or mBCC achieved a partial (decrease in tumor size) or complete (no tumor present) tumor response after treatment, with a complete response occurring in one patient (6.25%) with laBCC treated with a twice-daily dose of 400 mg for 4 months. A strong association between BCC tumor response and Hh pathway activation, as determined by a five-gene Hh signature reverse transcriptase polymerase chain reaction assay, was found. Sufficient tumor samples were available for nine BCC patients, with all (100%) showing five-gene Hh path activity after treatment with sonidegib (Table).

In an additional phase I trial, the maximum tolerated dose of sonidegib was investigated in patients with advanced solid tumors.<sup>7</sup> Twenty-one Japanese patients (group 1) were treated with either 400 or 600 mg once daily for a median of 88 and 86 days, respectively. Twenty-four patients from Hong Kong and Taiwan (group 2) were treated with 400 mg (n=12, 76

From the Department of Medicine, University of Toronto School of Medicine, Toronto, Ontario, Canada;<sup>1</sup> Mediprobe Research Inc., London, Ontario, Canada;<sup>2</sup> the Department of Medicine Baylor University Medical Center,<sup>3</sup> the Department of Dermatology,<sup>4</sup> and Department of Family Practice,<sup>5</sup> University of Texas Southwestern Medical School, the Dermatology Treatment and Research Center, Dallas, TX;<sup>6</sup> and the Belle Meade Dermatology, Nashville, TN<sup>7</sup>

Address for Correspondence: Aditya K. Gupta, MD, PhD, FRCPC, 645 Windermere Road, London, Ontario, Canada N5X 2P1  
• E-mail: agupta@execulink.com

**Table. Study Characteristics, Dosing Regime, and Efficacy Rates of Odomzo in Phase I–II Clinical Trials<sup>8–13</sup>**

AUTHOR	REGIME	EFFICACY RATES	
<b>Phase I trials (n=148)</b>			
Rodon et al, 2014 <sup>9</sup> (n=103) 63 M, 40 F Mean age (years): 59.0 (22–87) 16 tumors treated	Escalating doses once (100, 200, 400, 800, 1000, 1500, or 3000 mg) or twice (250, 400, or 750 mg) daily, continuously, 28-day cycle measured at day 15	6.3% (1/16) complete response laBCC or mBCC 31.3% (5/16) partial response laBCC or mBCC	
Minami et al, 2016 <sup>8</sup> (n=45) 21 M, 24 F Median age (years): group 1, 62 (20–71); group 2, 53 (31–69)	Group 1: (n=12) 400 mg, (n=9) 600 mg; group 2: (n=12) 400 mg, (n=8) 600 mg, (n=4) 800 mg, once daily; continuously 28-day cycle for a median of Group 1: 88, 86, Group 2: 76, 89 or Group 3: 74 days	Group 1 (n=21): 23.8% (5/21) stable disease 71.4% (15/21) progressive disease 4.8% (1/21) lost to FU	Group 2 (n=24): 41.7% (10/24) stable disease 37.5% (9/24) progressive disease 20.8% (5/24) lost to FU
<b>Phase II trials (n=775)</b>			
Migden et al, 2015 <sup>11</sup> BOLT (n=230) 144 M, 86 F Median age (years): group 1, 67 (25–92); group 2, 65 (24–93)	Group 1: 200 mg Group 2: 800 mg Once daily on a continuous dosing schedule for up to 30 days  =	Group 1 (per central review) (n=79): 3.0% (2/66) laBCC complete response 43.9% (29/66) laBCC, 15.4% (2/13) mBCC partial response 43.9% (29/66) laBCC, 76.9% (10/13) mBCC stable disease 1.5% (1/66) laBCC progressive disease 7.6% (5/66) laBCC, 7.7% (1/13) mBCC unknown	Group 2 (per central review) (n=151): 35.2% (45/128) laBCC, 17.4% (4/23) mBCC partial response 43.0% (55/128) laBCC; 65.2% (15/23) mBCC stable disease 4.3% (1/23) mBCC progressive disease 21.9% (28/128) laBCC; 13.0% (3/23) mBCC unknown
Dummer et al, 2016 <sup>10</sup> BOLT FU (n=230) Same as above	Same as above, 12 month FU data	Group 1 (per central review) (n=79): 4.5% (3/66) laBCC complete response 53.0% (35/66) laBCC, 7.7% (1/13) mBCC partial response 33.3% (22/66) laBCC, 84.6% (11/13) mBCC stable disease 1.5% (1/66) laBCC progressive disease 7.6% (5/66) laBCC, 7.7% (1/13) mBCC unknown	Group 2 (per central review) (n=151): 1.6% (2/128) laBCC complete response 42.2% (54/128) laBCC, 17.4% (4/23) mBCC partial response 37.5% (48/128) laBCC, 73.9% (17/23) mBCC stable disease 0.8% (1/128) laBCC, 4.3% (1/23) mBCC progressive disease 18.0% (23/128) laBCC, 4.3% (1/23) mBCC unknown
Quinlan et al., 2016 <sup>12</sup> (n=545) 399 M, 146 F Median age (years): group 1, 62.0; group 2, 34.5	Pooled analysis of four patient studies; measured at 17 weeks	Treatment group: 341 patients (n=211, 102, 21, and 7 from the phase II pivotal study A2201, study X2101, study X1101, and study B2209, respectively) Control group: 204 healthy volunteers (n=146, 36, 16, and 6 from study A2114, study A1102, study A2108, and study A2110, respectively) QTcF steady-state concentrations (200 and 800 mg): all below 5 ms Highest mean ΔQTcF: (200 mg) –3.9 ms at week 17 pre dose and (800) 2.7 ms at 2 hours post dose	
<b>Phase I + II trials (n=667)</b>			
Zhou et al, 2016 <sup>13</sup> BOLT and three other trials (n=667) 408 M, 260 F Mean age (years): group 1, 65; group 2, 66; group 3, 62	Group 1/2: 200 or 800 mg once daily for 12 weeks Group 3 PK-CK: 100–3000 mg once daily and 250–750 mg twice daily for 12 weeks	PK-FAS: group 1 (n=190), group 2 (n=141) and group 3 (n=336) Week 5: C <sub>min</sub> vs ORR indicated no relationship between Odomzo 200 or 800 mg dose and probability of complete response or partial response No exposure-efficacy relationship indicated from the progression-free survival and time to tumor response analyses Increased exposure associated with a greater risk of grade 3 or 4 CK elevation, with lower risk in women than men when C <sub>min</sub> used in the model	

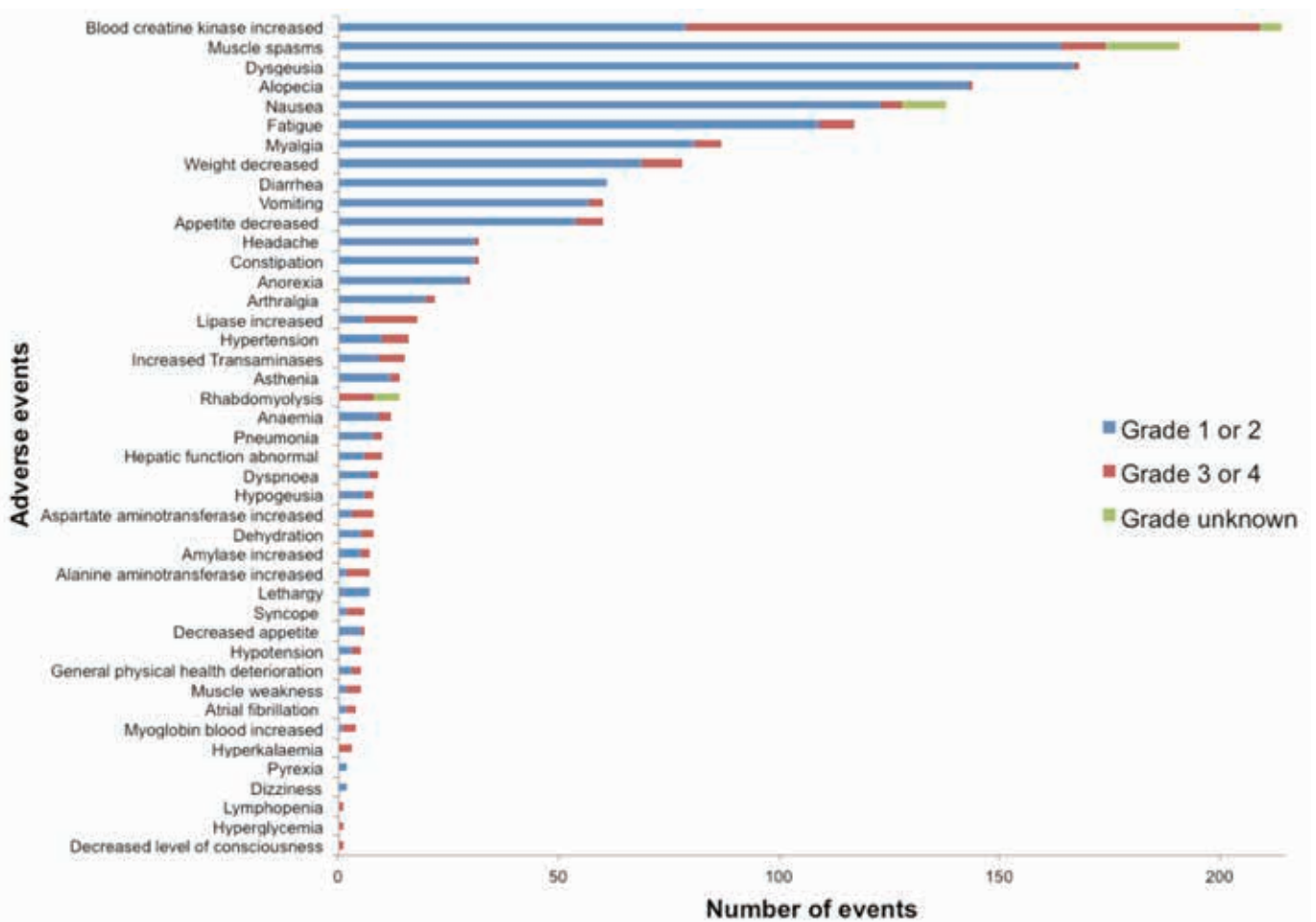
days) or 600 mg (n=8, 89 days) or 800 mg (n=4, 74 days). The maximum tolerated dose was established as 600 mg. The dose-limiting toxicity was caused by elevated creatine kinase in both treatment groups (Table).

**PHASE II CLINICAL DATA**

The first phase II clinical trial (Basal Cell Carcinoma Outcomes with LDE225 Treatment [BOLT]) was published in 2015 and collected data from 58 centers across 12 countries.<sup>10</sup> Patients who had either laBCC not amenable to curative surgery or radiation, or mBCC were included for review and received 200 or 800 mg of sonidegib once daily (n=230). Primary results showed that sonidegib 200 mg once daily (group 1) produced a complete response in 2 of 66 (3.0%) and a partial response in 29 of 66 (43.9%) participants with laBCC; 800 mg once daily (group 2) produced a complete response in 2 of 13 (15.4%) patients with mBCC, a partial response in 45 of 128 (35.2%) for laBCC, and a partial response in 4 of 23 (17.4%) for mBCC. The 12-month

follow-up data for group 1 showed a complete response in 3 of 66 (4.5%) patients, a partial response in 35 of 66 (53.0%) for laBCC, and a partial response in 1 of 13 (7.7%) for mBCC.<sup>9</sup> Data for group 2 showed a complete response in 2 of 128 (1.6%) patients, a partial response in 54 of 128 (42.2%) for laBCC, and a partial response in 4 of 23 (17.4%) for mBCC (Table).

In an additional phase II trial, pharmacokinetic-pharmacodynamic analysis was performed to test whether prolongation of the QT/QTc interval occurred during extended use of sonidegib.<sup>11</sup> Results showed there was no QT prolongation associated with sonidegib. No clear exposure and efficacy relationship was found with sonidegib in an additional analysis.<sup>12</sup> There was, however, a positive relationship between sonidegib exposure and grade 3 creatine phosphokinase elevation. Comparing estimated steady-state concentration minimums, 800 mg once daily was found to deliver an exposure level 2.3-fold higher than a dose of 200 mg once daily (Table).



**Figure.** Adverse events of Odomzo reported in phase I-II clinical trials.<sup>8-13</sup>

## CONCLUSIONS

Sonidegib has, on the strength of the Phase II data, been approved by the Food and Drug Administration for the treatment of laBCC recurring after surgery or radiation therapy, and for individuals who are not candidates for surgery or radiation therapy. At the time of writing, no phase III trials involving sonidegib have been published. There is a 'black box' warning for sonidegib for embryonic/fetal toxicities.<sup>7</sup> Adverse events associated with sonidegib were mostly grade 1 (mild) and grade 2 (moderate) in severity (eg, nausea and fatigue) (Figure 1). A malfunction of the Hh signaling pathway involving one or both P53 and MC1R gene mutations increases the risk of laBCC development; thus medical management with Smo receptor antagonists, such as oral sonidegib and vismodegib, seems to be an effective strategy against the progression of laBCC.<sup>14</sup>

The approval of sonidegib adds to the armamentarium of treatments for recurrent laBCC that could improve patient quality of life. There is a lack of head-to-head, long-term studies comparing sonidegib to its chief competitor vismodegib and to other oral treatments approved for the treatment of laBCC, and such studies would be valuable. Sonidegib may be an option for patients with laBCC and for physicians searching for a nonsurgical alternative or additional therapy for this disease.

## REFERENCES

- Demers AA, Nugent Z, Mihalcioiu C, Wiseman MC, Kliwer EV. Trends of nonmelanoma skin cancer from 1960 through 2000 in a Canadian population. *J Am Acad Dermatol*. 2005;53:320–328.
- Gandhi SA, Kampp J. Skin cancer epidemiology, detection, and management. *Med Clin North Am*. 2015;99:1323–1335.
- Cakir BÖ, Adamson P, Cingi C. Epidemiology and economic burden of nonmelanoma skin cancer. *Facial Plast Surg Clin N Am*. 2012;20:419–422.
- Muzic JG, Schmitt AR, Wright AC, et al. Incidence and trends of basal cell carcinoma and cutaneous squamous cell carcinoma. *Mayo Clin Proc*. 2017 1;92:890–898.
- National Comprehensive Cancer Network. Basal Cell Skin Cancer. NCCN Clinical Practice Guidelines in Oncology. <https://www.scribd.com/doc/295173448/Basal-Cell-Skin-Cancer-NCCN-Guidelines>. Accessed August 21, 2017.
- U.S. Food and Drug Administration. Odomzo. [https://www.accessdata.fda.gov/drugsatfda\\_docs/label/2015/205266s000lbl.pdf](https://www.accessdata.fda.gov/drugsatfda_docs/label/2015/205266s000lbl.pdf). Accessed August 21, 2017.
- Minami H, Ando Y, Ma BBY, et al. Phase I, multicenter, open-label, dose-escalation study of sonidegib in Asian patients with advanced solid tumors. *Cancer Sci*. 2016;107:1477–1483.
- Rodon J, Tawbi HA, Thomas AL, et al. A phase I, multicenter, open-label, first-in-human, dose-escalation study of the oral smoothed inhibitor sonidegib (LDE225) in patients with advanced solid tumors. *Clin Cancer Res*. 2014;20:1900–1909.
- Dummer R, Guminski A, Gutzmer R, et al. The 12-month analysis from Basal Cell Carcinoma Outcomes with LDE225 Treatment (BOLT): A phase II, randomized, double-blind study of sonidegib in patients with advanced basal cell carcinoma. *J Am Acad Dermatol*. 2016;75:113–125.e5.
- Migden MR, Guminski A, Gutzmer R, et al. Treatment with two different doses of sonidegib in patients with locally advanced or metastatic basal cell carcinoma (BOLT): A multicentre, randomised, double-blind phase 2 trial. *Lancet Oncol*. 2015;16:716–728.
- Quinlan M, Zhou J, Hurh E, Sellami D. Exposure-QT analysis for sonidegib (LDE225), an oral inhibitor of the hedgehog signaling pathway, for measures of the QT prolongation potential in healthy subjects and in patients with advanced solid tumors. *Eur J Clin Pharmacol*. 2016;72:1427–1432.
- Zhou J, Quinlan M, Hurh E, Sellami D. Exposure-response analysis of sonidegib (LDE225), an oral inhibitor of the hedgehog signaling pathway, for effectiveness and safety in patients with advanced solid tumors. *J Clin Pharmacol*. 2016;56:1406–1415.
- U.S. Food and Drug Administration. FDA approves new treatment for most common form of advanced skin cancer. <https://www.fda.gov/NewsEvents/Newsroom/PressAnnouncements/ucm455862.htm>. Accessed August 21, 2017.
- Sekulic A, Von Hoff D. Hedgehog pathway inhibition. *Cell*. 2016;164:831.

### VINTAGE LABEL

**CAUTION: Avoid habitual use. Do not use in case of acute abdominal pain, nausea and vomiting which may be indicative of appendicitis.**

Courtesy of BuyEnlarge, Philadelphia, PA



## PERILS OF DERMATOPATHOLOGY

W. Clark Lambert, MD, PhD, Section Editor

# Aggressive Mimicry in Dermatology: When a Basal or Squamous Cell Carcinoma Mimics a Spindle Cell Tumor

Ann M. John, BA; Parmvir Singh, BS; Marc Z. Handler, MD; W. Clark Lambert, MD, PhD

“The skin was that of a sheep, but the activities were those of a wolf”—Laurentius Abstemius, 15th-century Italian philosopher

**M**alignant spindle cell tumors are typically diagnosed by biopsy, often confirmed with immunohistochemical staining, and treated by excision with wide margins; however, the more benign variants of spindle cell tumors do not require such aggressive treatment. These include leiomyomas, angioleiomyomas, neurofibromas, schwannomas, neurothekeomas, hemangiomas, glomus tumors, myofibromas, and spindle cell lipomas. Immunostaining is recommended to confirm the benign nature of these tumors, not only due to the difference in treatment of benign and malignant spindle cell tumors, but also because other malignant tumors may also have spindle cell components or even be disguised as spindle cell tumors.

## AN ILLUSTRATIVE PATIENT

Over a 3-year period, a 57-year-old man developed a soft, nodular, asymptomatic, flesh-colored lesion on the skin over the lateral aspect of the left clavicle. The lesion was focally ulcerated, but no telangiectasia was noted. The lesion was initially diagnosed, based on histopathologic presentation on hematoxylin and eosin staining, as a spindle cell tumor of uncertain differentiation and uncertain behavior (Figures 1 and 2). Subsequently, BerEP4 staining identified the lesion as a basal cell carcinoma (BCC) (Figures 3 and 4). The patient was treated appropriately for a malignant tumor by excision with wide margins.

## DISCUSSION

BCCs have been previously reported to contain histologic areas with a proliferation of spindle cells.<sup>1</sup> A rare entity, known as sarcomatoid BCC, may contain spindle cell and basal cell

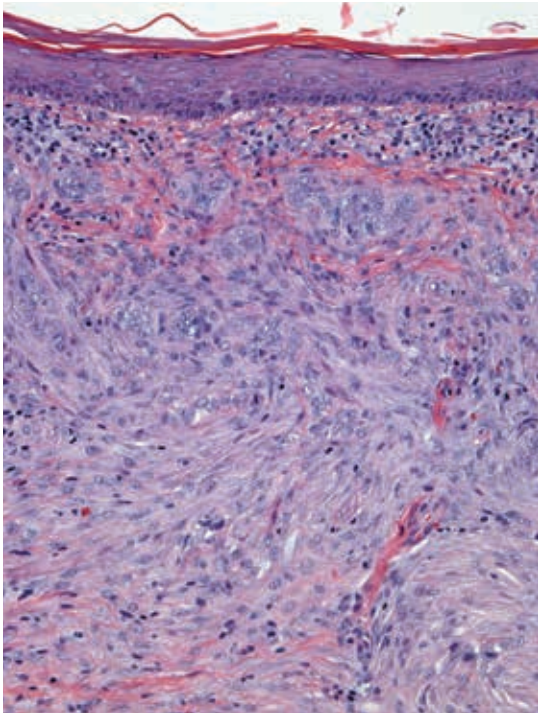
components. The spindle cell component can be homologous or heterologous. Previous reports have suggested that investigating these tumors under low magnification may lead to missing the BCC; higher power magnification and confirmatory staining can highlight typical features of BCC.<sup>2-4</sup> As this particular variant has aggressive behavior and metastatic potential, prompt recognition of the malignant component is important. In addition, there may be spindle cell tumor and BCC in the same lesion. One report described a “hybrid” tumor with characteristics of BCC and myoepithelioma. The spindle cells stained strongly with p63.<sup>5</sup> Neurofibroma and BCC have also been reported to occur in the same lesion, presenting clinically as nonulcerating nodules.<sup>6,7</sup>

Spindle cell squamous cell carcinoma is uncommon but not rare. This variant is a relatively aggressive tumor often found in patients with a history of radiation burn, scars, or organ transplantation; it has the potential for local recurrence and distant metastases.<sup>8</sup> Histologically, this tumor has a spindle cell component that infiltrates the dermis as individual cells or nests of cells. The spindle cells are interspersed with varying degrees of squamous cell carcinoma features. This tumor usually stains positive for 34βE12, p63 and low-molecular-weight keratin (AE1/AE3).<sup>8,9</sup>

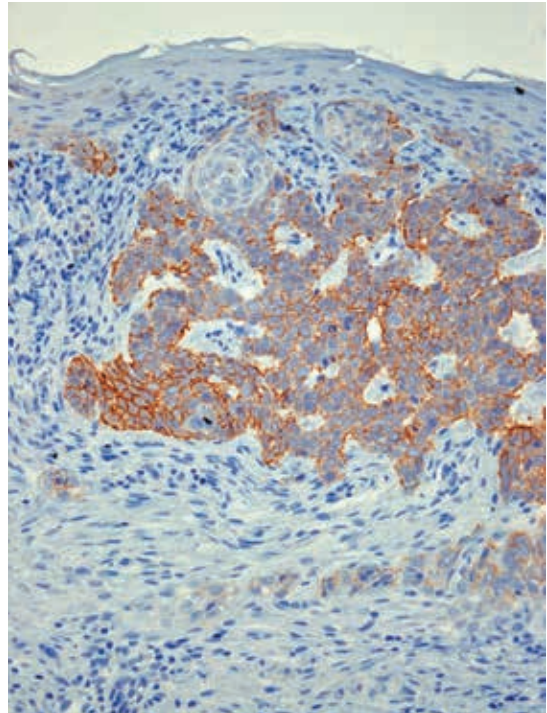
Multiple theories for the presence of two histologic subtypes in the same lesion have been proposed. The *collision theory* states that two independent tumors may coincidentally collide in the same location, explaining the presence of both histologic subtypes. This theory may account for some cases, but it is not the most widely accepted explanation. The *composition theory* states

From the Department of Dermatopathology, Department of Dermatology, and Department of Pathology and Laboratory Medicine, Rutgers – New Jersey Medical School, Newark, NJ

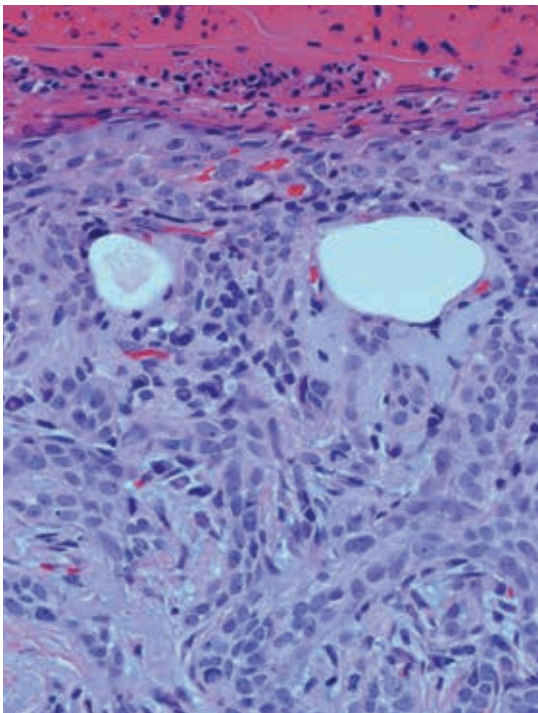
Address for Correspondence: W. Clark Lambert, MD, PhD, H576 Medical Science Building, Rutgers-New Jersey Medical School, 185 South Orange Avenue, Newark, NJ 07103 • E-mail: lamberwc@njms.rutgers.edu



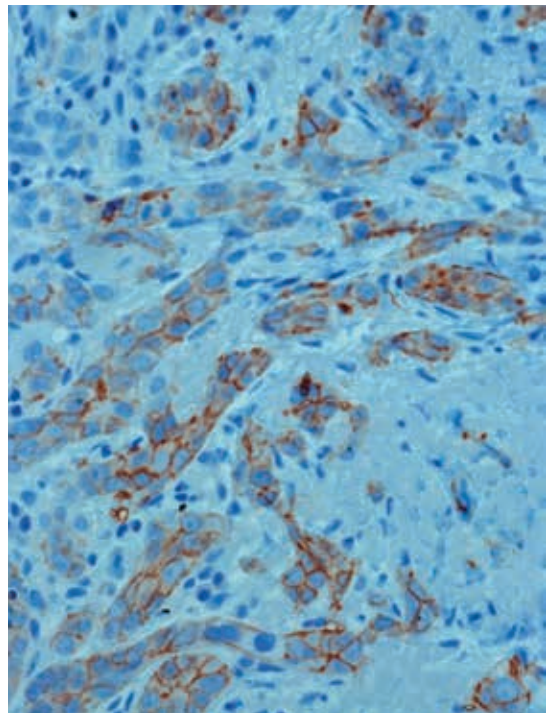
**Figure 1.** Case 1: basal cell carcinoma resembling a spindle cell tumor (hematoxylin and eosin stain, magnification  $\times 270$ ).



**Figure 3.** Case 1: BerEP4 stain identifying the lesion as a basal cell carcinoma (BerEP4 stain, magnification  $\times 270$ ).



**Figure 2.** Case 1: basal cell carcinoma resembling a spindle cell tumor; ulcerated area. (hematoxylin and eosin stain, magnification  $\times 540$ ).



**Figure 4.** Case 1: BerEP4 stain confirming basal cell carcinoma, showing the cellular detail (BerEP4 stain, magnification  $\times 540$ ).

that the spindle or stromal cell component of the tumor is actually a reaction to the malignant epithelial component. The *combination theory* suggests that both components arise from a common progenitor cell that undergoes divergent differentiation. Finally, the *conversion theory* suggests that the spindle cell component arises from a metaplastic transformation of the epithelial component. This last theory is most widely accepted due to genetic evidence of monoclonality in lesions, including both histologic subtypes, showing identical genetic mutations of p53 and k-ras, loss of heterozygosity, and similar genetic alterations.<sup>4</sup>

Although it is appropriate to be conservative in the treatment of benign spindle cell tumors, dermatologists should be aware of the occasional malignant tumor that may be hidden amidst the bland ocean of spindle cells. We recommend confirmatory staining of spindle cell tumors for two reasons:

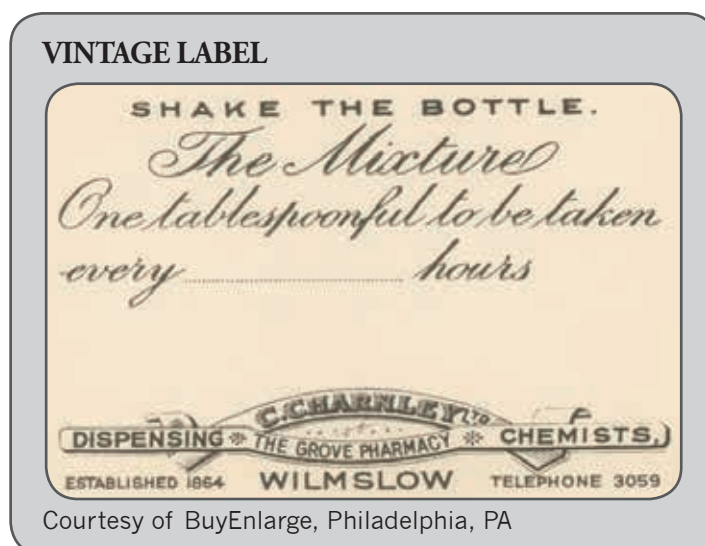
- first, as an aid in definitively differentiating a benign spindle cell tumor from its malignant counterpart, especially as the clinical differentiation is often unclear;
- second, because, while rare, there a potential for multiple histologic subtypes to exist in the same lesion.

## CONCLUSIONS

When the clinical-pathologic correlation is not clear, we recommend investigation for another diagnosis, such as BCC or squamous cell carcinoma.

## REFERENCES

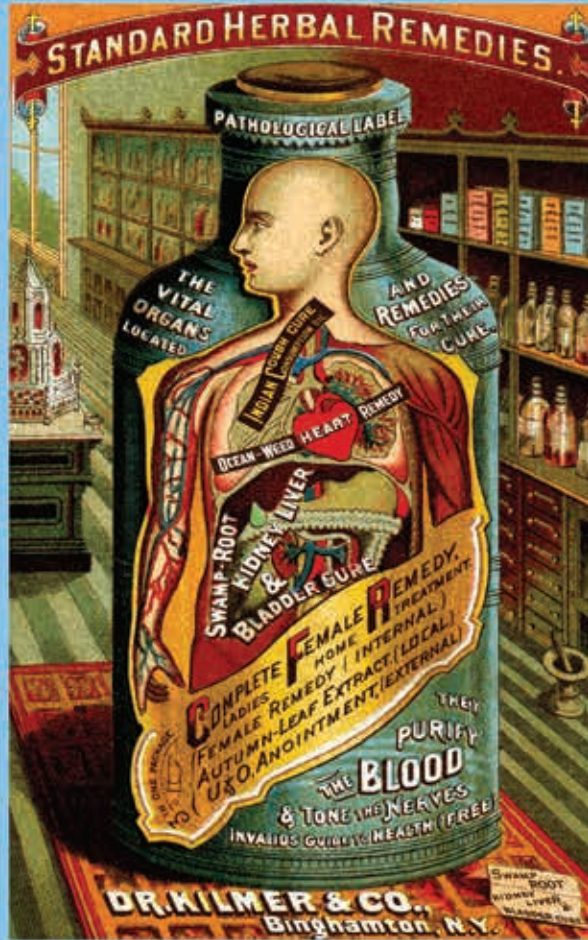
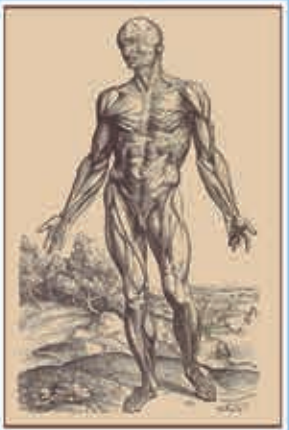
- 1 Ziari K, Behdad B, Mohammadshahi A, Pirasteh HR, Sharifi MD, Dadpay M. Cellular and biological evaluation and diagnostic immunohistochemistry of cytokeratin 15/19 expression in distinguishing cutaneous basal cell carcinoma. *Biologicals*. 2015;43:181–185.
- 2 Fernandez-Flores A. Study of D2-40 immunoexpression of the spindle cell areas of a metaplastic basal cell carcinoma (sarcomatoid basal cell carcinoma). *Appl Immunohistochem Mol Morphol*. 2012;20:518–522.
- 3 Harvey NT, Sinha A, Houghton DC, et al. Basal cell carcinoma: A report of 4 cases and review of the literature. *Am J Dermatopathol*. 2014;36:483–489.
- 4 Bigby SM, Charlton A, Miller MV, Zwi LJ, Oliver GF. Biphasic sarcomatoid basal cell carcinoma (carcinosarcoma): Four cases with immunohistochemistry and review of the literature. *J Cutan Pathol*. 2005;32:141–147.
- 5 Huang Y. Basal cell adenoma in the parotid: A bizarre myoepithelial-derived stroma rich variant. *Int J Clin Exp Pathol*. 2014;7:4512–4515.
- 6 Mohammadi A, Rosa M, Rhatigan R. Eyelid basal cell carcinoma associated with solitary neurofibroma. *J Cutan Pathol*. 2010;37:707–709.
- 7 Boyd AS, Rapini RP. Cutaneous collision tumors. An analysis of 69 cases and review of the literature. *Am J Dermatopathol*. 1994;16:253–257.
- 8 Trieu D, Drosou A, Goldberg LH, Kimyai-Asadi A. Detecting spindle cell squamous cell carcinomas with toluidine blue on frozen sections. *Dermatol Surg*. 2014;40:1259–1260.
- 9 Lee JH, Lee YB, Kim JW, Yu DS. Cutaneous spindle cell squamous cell carcinoma. *Ann Dermatol*. 2015;27:113–115.



Courtesy of BuyEnlarge, Philadelphia, PA

# Vintage Medical Art

...and thousands of other reproductions.



## DERMATOLOGY

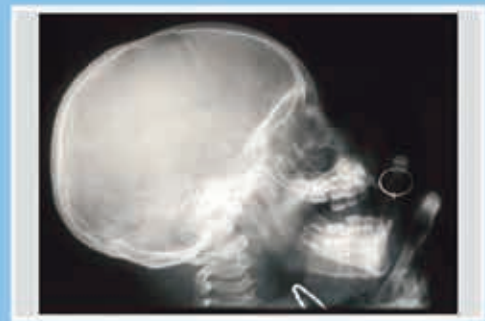- AVAILABLE IN A VARIETY OF SIZES
- FRAMED IN PAPER OR ON CANVAS
- VIEW ONLINE AT:

[WWW.BUYENLARGE.COM](http://WWW.BUYENLARGE.COM)  
or [WWW.POSTERIMAGEART.COM](http://WWW.POSTERIMAGEART.COM)

## GENERAL MEDICINE



[BUYENLARGE.COM](http://BUYENLARGE.COM)  
2900 S. 20TH ST.  
PHILA., PA. 19145  
1-215-551-8700  
[PPIERCE@BUYENLARGE.COM](mailto:PPIERCE@BUYENLARGE.COM)



## THE HEYMANN FILE

Warren R. Heymann, MD, Section Editor

# The Prescience of Bernie Ackerman: The Road from “Pseudoleukemia Cutis” to “Intralymphatic Proliferation of T-cell Lymphoid Blasts (IPTCLBs)”

Warren R. Heymann, MD

“I have been accused, perhaps justifiably, of having written more than I have read. I would not presume to speak for the readers of my writings, but I can speak for myself: How enormously instructive and pleasurable it has been! I hope that readers feel the same.” —A. Bernard Ackerman<sup>1</sup>

As with anyone’s passing, life goes on and memories fade. Periodically, there is a jolt—a reminder of a person’s brilliance and legacy left behind. I never trained directly with Bernie but had the good fortune to attend his lectures and become acquainted with him personally. There is no dermatopathologist alive who has not been influenced by his teachings, whether they agree with him or not. Based on the quote above, I can assure him posthumously that his writings are still incisive and instructive.

In 1977, prior to the advent of immunohistochemistry, Ackerman and Tanski described “pseudoleukemia cutis.”<sup>2</sup> The following is the abstract from the paper:

Histologic sections from a solitary cystic cutaneous lesion that showed atypical mononuclear cells in the dermis and within blood vessels were diagnosed by several general pathologists and dermatopathologists as leukemia cutis. The patient, who had no other cutaneous lesions, was consequently submitted to an extensive investigation for leukemia, which proved negative. Additional and deeper sections from the original block revealed that the cellular infiltrate so suspicious of leukemia cutis was secondary to rupture of a lesion of molluscum contagiosum. The correct histopathologic diagnosis, therefore, was pseudoleukemia cutis. The lessons of the case are that 1) further study of the specimen, solitary as it was and asymptomatic as the patient was, would have obviated worry and

the expense and inconvenience of an extensive systemic investigation, and that 2) the diagnosis of leukemia cutis should never be made solely on the basis of histologic sections of skin, but rather after examination of blood and bone marrow.

In the photomicrographs in their paper, one can clearly see atypical mononuclear cells within vessels. It is certainly understandable why seasoned pathologists thought this patient had leukemia.

## INTRALYMPHATIC PROLIFERATION OF T-CELL LYMPHOID BLASTS (ILPTCLBS)

Fast forward four decades to the increasingly reported concept of ILPTCLBs—intralymphatic proliferation of T-cell lymphoid blasts. The most recent report is that of a 77-year-old man who was treated with antibiotics for a hip prosthesis infection. Eight weeks later, he developed an eruption characteristic of DRESS (drug reaction with eosinophilia and systemic symptoms) syndrome, accompanied by fever and eosinophilia. Cutaneous biopsy revealed an atypical T-cell proliferation within dermal lymphatic vessels. The lymphocytes were mid-sized, with mitoses and apoptotic figures. They were CD3+, CD4+, CD5+, and some were CD30+. There was no T-cell receptor clonal rearrangement. Complete regression of the cutaneous eruption and eosinophilia was observed after ceasing treatment with antibiotics. The diagnosis was that of a benign atypical intralymphatic

From the Division of Dermatology, Departments of Medicine and Pediatrics, Cooper Medical School of Rowan University, Marlton, NJ

Address for Correspondence: Warren R. Heymann, MD, Division of Dermatology, Departments of Medicine and Pediatrics, Cooper Medical School of Rowan University, 100 Brick Road, Suite 306, Marlton, NJ 08053 • E-mail: wrheyman@gmail.com

T-cell proliferation associated with DRESS syndrome. The authors assert that the occurrence of atypical dermal CD30+ T cells in cutaneous biopsy during benign reactive conditions such as arthropod bites or scabies is well known. The intralymphatic localization of atypical reactive lymphocytes, however, is much less common and represents a diagnostic pitfall because it can suggest an aggressive intravascular lymphoma.<sup>3</sup>

ILPTCBs have also been noted in other inflammatory disorders such as hidradenitis suppurativa<sup>4</sup> and lichen sclerosus.<sup>5</sup> The histopathologic criteria for the diagnosis of ILPTCBs are: (1) the presence of an associated inflammatory disorder; (2) clusters of large atypical lymphoid cells confined to D2-40+ lymphatic vessels, although scattered atypical extravascular cells are common; (3) A T-cell phenotype without aberrant features (no loss of pan-T-cell markers, no aberrant double positivity/negativity of CD4 and CD8); (4) EBER-1 negativity for the Epstein-Barr virus; and (5) a polyclonal infiltrate as detected by polymerase chain reaction.<sup>4</sup>

#### THE DIFFERENTIAL DIAGNOSIS OF ILPTCLBS

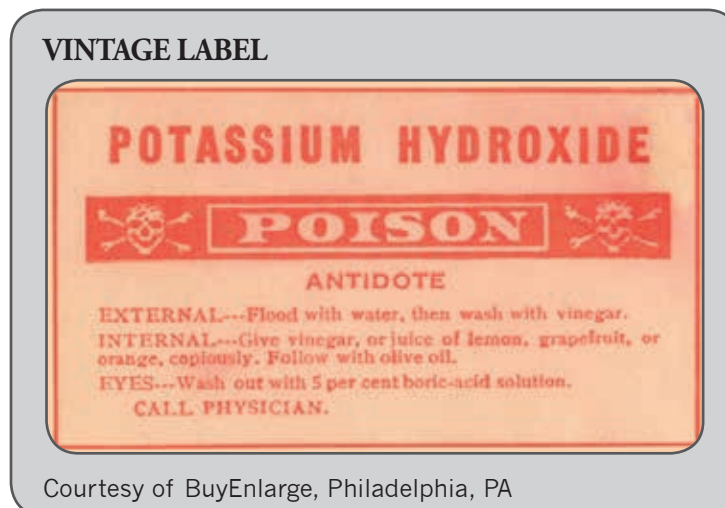
Intralymphatic histiocytosis enters the histologic differential diagnosis, and is classically associated with rheumatoid arthritis.<sup>3</sup> Immunohistochemistry clearly differentiates intralymphatic histiocytosis from ILPTCBs; in intralymphatic histiocytosis, the infiltrate is positive for CD68 and CD163, in contrast to the T-cell profile observed in ILPTCB.<sup>4</sup> Of course intravascular lymphoma or leukemia must always be ruled out. Intravascular lymphoma or leukemia is an aggressive disease, with most cases representing a diffuse large B-cell lymphoma, although a rare T-cell variant has been reported, including cases with CD30 expression.<sup>5</sup> Recently, an indolent form of intralymphatic cutaneous anaplastic large cell lymphoma/lymphomatoid papulosis, with CD30 positivity, has been reported.<sup>6</sup>

#### CONCLUSIONS

When intralymphatic atypical lymphocytes are appreciated, it is essential to look at the clinical context, perform immunohistochemical stains, and check for clonality, in order to differentiate a benign process from a true lymphoma. As Bernie taught us, clarity in the writing and linguistics of dermatopathology is essential to translate what is seen microscopically to useful clinical information. I am not sure that a report of ILPTCB would mean anything to the referring dermatologist without a detailed explanation. Perhaps we would be best utilizing Bernie's original term, "pseudoleukemia cutis."

#### REFERENCES

- 1 Weyers W. A. Bernard Ackerman 1936-2008. *Am J Dermatopathol.* 2009;31:740-761.
- 2 Ackerman AB, Tanski EV. Pseudoleukemia cutis. Report of a case in association with molluscum contagiosum. *Cancer.* 1977;40:813-817.
- 3 Weingertner N, Mitcov M, Chenard MP, Cribier B. Intralymphatic CD30+ T-cell proliferation during DRESS: A mimic of intravascular lymphoma. *J Cutan Pathol.* 2016;43:1036-1040.
- 4 Calamaro P, Lorenzi L. Intralymphatic proliferation of T-cell lymphoid blasts in the setting of hidradenitis suppurativa. *Am J Dermatopathol.* 2016;38:536-540.
- 5 Kempf W, Keller K, John H, Domman-Scherrer C. Benign atypical intravascular CD30+ T-cell proliferation: A recently described reactive lymphoproliferative process and simulator of intravascular lymphoma. *Am J Clin Pathol.* 2014;142:694-699.
- 6 Samols MA, Su A, Ra S, Cappel MA, et al. Intralymphatic cutaneous anaplastic large cell lymphoma/lymphomatoid papulosis: Expanding the spectrum of CD30-positive lymphoproliferative disorders. *Am J Surg Pathol.* 2014;38:1203-1211.



## PHOTO CAPSULE

Snejina Vassileva, MD, PhD, Section Editor

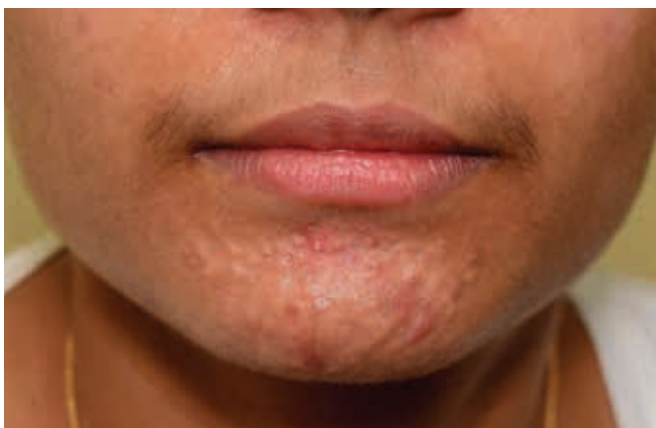# Gnathophyma

Piyush Kumar, MD;<sup>1</sup> Anupam Das, MD<sup>2</sup>

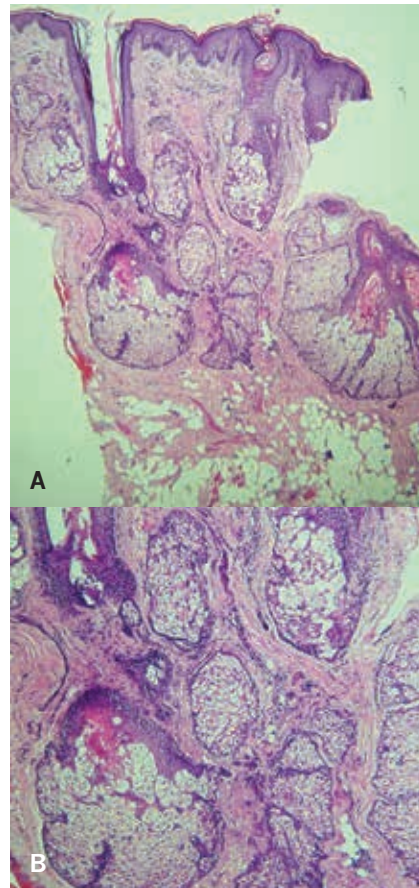
**A** 23-year-old woman presented with asymptomatic, flesh-colored papules of 8 years' duration on the chin. She gave a history of recurrent erythematous papules and pustules that used to subside in 2–3 weeks. On examination, multiple, grouped, flesh-colored papules along with a few erythematous papules were noted on the chin (Figure 1). The rest of the mucocutaneous examination was unremarkable except for a few erythematous papules around the nose.

Histopathology of a specimen taken from a flesh-colored papule showed numerous hypertrophied sebaceous glands with extensive surrounding fibrosis. A superficial and mid-perivascular and periappendageal lymphoplasmocytic infiltrate were noted (Figure 2). On clinicopathological correlation, a diagnosis of gnathophyma was made.

Rhinophyma is a well-known complication of rosacea, but phymas of other regions (chin, helix, forehead, eyelids) are uncommon and can cause confusion in diagnosis. The phymatous changes affecting areas other than the nose are usually infrequent and do not occur as an isolated entity.<sup>1</sup> Our patient had almost exclusive involvement of the chin—a rare presentation.



**Figure 1.** Grouped, flesh-colored papules on the chin.



**Figure 2.** (A) Numerous hypertrophied sebaceous glands with a perivascular and periappendageal lymphoplasmocytic infiltrate (hematoxylin and eosin, original magnification  $\times 40$ ). (B) Hypertrophied sebaceous glands with extensive surrounding fibrosis (hematoxylin and eosin, original magnification  $\times 400$ ).

## REFERENCE

- 1 Schintler MV, Arbab E, Aberer W, Spindel S, Scharnagl E. Surgical management of extensive gnathophyma. *J Eur Acad Dermatol Venereol.* 2006;20:1325–1327.

From the Department of Dermatology, Katihar Medical College and Hospital, Katihar,<sup>1</sup> and KPC Medical College and Hospital, Kolkata, West Bengal,<sup>2</sup> India

Address for Correspondence: Piyush Kumar, MD, Department of Dermatology, Katihar Medical College and Hospital, Katihar, India 854105 • E-mail: docpiyush@gmail.com

A+MD

A+MD

A+MD

# THE INTERSECTION OF DISEASE AND DESIRE DERMATOLOGY



# A+MD

AESTHETIC & MEDICAL DERMATOLOGY SYMPOSIA

MAY 9-12, 2018 - COEUR D'ALENE, ID

**This intimate and exciting educational symposia is happening again at one of the great resorts of the beautiful Northwest...The Coeur d'Alene.**

A+MD is designed for physicians, nurse practitioners, physician assistants, office managers, cosmetic consultants, and those interested in learning about the intersection of disease and desire dermatology and the psychological impact of aesthetic improvement.

Our distinguished faculty is headed by Wm. Philip Werschler, MD, and our Scientific Advisory Board is comprised of George Martin, MD, and Vic A. Narukur, MD.

**PRE-CONFERENCE WORKSHOPS** on Fillers & Toxins Essentials and Advanced Techniques with Energy Devices. **MAIN PROGRAM HIGHLIGHTS INCLUDE:** The many fundamentals of Aesthetic Medicine & Practice • Special considerations of skin of colour • Neurotoxins and dermal fillers • Energy-based skin care • Psoriasis management • Rosacea, acne and complexion disorders • Actinic Keratosis management • Nonmelanoma skin cancer treatment • Pigmented lesion management • Pigmentation disorders • Practice management • Development of the Cosmetic Office Practice team • Advanced cosmetic surgical procedures for the office • Age management medicine for dermatology • Concierge practice • Clinical research • **Plus many more "Need to Know" topics.**

**REGISTER NOW** by visiting [AMDsym.com](http://AMDsym.com)

#A+MD



SOCIETY HIGHLIGHTS OF THE 58TH ANNUAL MEETING OF THE  
 NORTH AMERICAN CLINICAL DERMATOLOGIC SOCIETY

# Gauchos to Glaciers!:

## April 18–27, 2017, Argentina and the Galapagos Islands



Robert S. Berger, MD

**JOINT SESSION WITH THE INTERNATIONAL  
 SOCIETY OF DERMATOLOGY: BUENOS AIRES,  
 ARGENTINA, APRIL 18**

Richard Spielvogel, MD (Philadelphia, PA) described horizontal sectioning of hair biopsies as the best way to obtain a correct diagnosis of hair disorders. The average hair count ranges up to 24 per section for this method, as opposed to four for vertical sections. Vertical sections may, however, be required to visualize the dermoepidermal junction.

Anthony V. Benedetto, DO (Philadelphia, PA) discussed avoiding postoperative surgical site infections by promoting wound healing with a topical silicone gel that is semioclusive, gas-permeable, and bacteriostatic. When applied to an open or closed wound, the agent forms a flexible, protective film barrier that contours to the wound surface, reducing transepidermal water loss and inflammation.

Dedee Murell, MD (Sydney, Australia) noted a 50-fold increased incidence of squamous cell carcinoma in recessive dystrophic epidermolysis bullosa (EB), which appears well differentiated but has a very poor prognosis with early metastasis. Squamous cell carcinoma can occur at a very young age (the youngest case described being 7 years old) and in all skin types, including on non-sun-exposed and recurrent trauma sites. Recessive dystrophic EB patients with squamous cell carcinoma have a much higher level of urinary basic fibroblast growth factor than individuals with other types of EB, or recessive dystrophic EB patients without squamous cell carcinoma.

sive dystrophic EB patients without squamous cell carcinoma.

**BARILOCHE, ARGENTINA, APRIL 24**

Allan Arbuckle, MD (Denver, CO), in his update on EB, reported that a skin biopsy is now sufficient instead of a kidney biopsy in diagnosing Alport syndrome. The most debilitating symptoms of EB simplex are hyperkeratosis of the hands and feet. Junctional EB with granulation tissue in the middle region of the face carries a poor prognosis, whereas patients with nonlethal forms develop nail abnormalities. Kindler syndrome shows skin fragility and photosensitivity with actinic keratoses detected in children as young as 5 years old.

Anthony V. Benedetto, DO, discussed use of botulinum toxin A in the lower region of the face, where the angle of the chin can be blunted. When injecting the platysmal band, the 2-unit injections should be administered very superficially.

A. Howland Hartley, MD (Leonardtown, MD) presented newly reported galactose- $\alpha$ 1,3 galactose sensitivity, the first reported allergy to a nonprotein. It had been described in patients taking cetuximab, and is now seen in the general population. There is a delayed reaction to the nonprotein allergen, which is found in mammalian meats and transmitted by a Lone Star Tick bite.

Isabel Maria del Pilar Casas, MD (Patagonia, Argentina) presented a wonderful “how to” approach for educating school age children in Argentina about sun

From the Department of Dermatology, Johns Hopkins University School of Medicine, Baltimore, MD, and Charles County Dermatology Associates, White Plains, MD

Address for Correspondence: Robert S. Berger, MD, Charles County Dermatology Associates, 4225 Altamont Place, Unit 3, White Plains, MD 20695 • E-mail: rsbcsb@aol.com

damage and protection. Because a child's attention span is about 7 minutes, brevity and interaction are critical, and the use of graphic photos should be avoided. See the excellent YouTube videos "The Riddles of the Sun" (in Spanish with English subtitles; <https://www.youtube.com/watch?v=mzaHSa8ghKw>) and "Acertijos del sol" (in Spanish; <https://www.youtube.com/watch?v=YC85bjbMtiw>).

#### **CALAFATE, ARGENTINA, APRIL 26–27 (FIGURE)**

John R. Hamill, MD (Tampa, FL) discussed the new use for tazarotene cream. Under occlusion, this retinoid can be used for treating squamous cell carcinomas that have developed on the legs as a result of radiation therapy for lichen planus.

H. Alan Arbuckle, MD (Denver, CO) emphasized that the most important component of wound care is treating the underlying cause. With moisture balance and protein balance being critical, necrotic tissue should be removed frequently, as the colonizing bacteria can create problems. Vaseline or occlusive dressings are preferred over wet-to-dry dressings.



**Figure.** Members of the North American Clinical Dermatologic Society in Calafate, Argentina. (Left to right) Kneeling: Drs Berger, Murrell, Hamill, and Benedetto. Crouching over kneeling: C. Berger, RN, Dr. C. Burns, S. Hamill, Dr. Ringrose, B. Spielvodel, E. Cornejo, D. Benedetto. First row standing: Dr. Organ, Dr. G. Burns, Dr. Spielvogel, Dr. Porkka, Dr. Kopersky. Back row: D. Byers, Dr. Bryg, Dr. Arbuckle, Guide, Guide, Dr. Hartley, W. Lee, T. Applebee.

Dedee Murrell, MD told the group about a newly discovered defect to the 19th gene (currently named KLHL24), which causes EB and is involved in degradation of keratin 14. The first gene therapy for a skin disease has been performed in junctional EB; this involved stem cells, using a retroviral vector grown into artificial skin equivalents.

Robert Bryg, MD (Olympia, WA) reminded the group that electronic medical records are not a panacea. Errors, uncommon abbreviations, cloning of notes, and just plain carelessness can lead to payment denial.

Paul Garson, MD (Hampton, NY) noted that the addictive substances of opium, alcohol, and cocaine have been present in society for hundreds of years. Addiction involves the pleasure center of the brain, where excitement about the expectant pleasure resulting from use leads to increased dopamine release, flooding the brain and producing the resulting pleasure. Tolerance ensues, requiring more substance use and then addiction.

#### **GALAPAGOS ISLANDS, MAY 2**

Robert S. Berger, MD (White Plains, MD) reported that the cost of drugs has worsened. Within the previous year, the price of generic medication had sky-rocketed (clobetasol being the most recent example). With respect to branded medications, Targretin (bexarotene) has been one of the more egregious examples of overpricing, increasing to almost \$31,000 per 60 g tube (with no generic available) and \$51,000 per 200 capsules (oral). A new generic bexarotene tablet costs \$24,000 to \$31,000 per 200 (as per <https://www.goodrx.com> price listings). Independent specialty pharmacies are making inroads in cost reductions, and some US states are considering legislation to cap drug costs.

#### **ANNUAL MEETING APRIL 10–20, 2018**

The 59th Annual Meeting will take place in New Zealand, with first sessions in Auckland on North Island, followed by Christchurch on South Island, April 10–20, 2018.

## VIGNETTES OF DERMATOLOGIC HISTORY

Mark Bernhardt, MD, Section Editor

# Ex-Lax®

Mark Bernhardt, MD

“The speaker recalled one case under consideration at the Vanderbilt Clinic, which was originally seen by Dr. Howard Fox, who sent him specimens of tissue to examine microscopically. In this case the lesions always appeared at the same site after the patient took a patent medicine called ‘ex lax.’” —WH Mook<sup>1</sup>

It seemed like a good idea at the time. The *Phylloxera* pest was devastating Hungary’s famous vineyards, and bootleg lower quality wines were ruining what was left of the region’s reputation. To detect adulteration, in 1893 the Hungarian Parliament mandated that all wines contain the additive phenolphthalein. Shortly thereafter, a nationwide epidemic of diarrhea broke out, demonstrating the hitherto unknown fact that phenolphthalein was not only an excellent acid-base indicator, but also a powerful purgative.

One of the first to profit from this serendipitous discovery was a Budapest pharmacist, Dr. D. Bayer. Although phenolphthalein itself is tasteless, he decided to enhance its appeal by adding sugar and vanilla flavoring. Dr. Bayer’s laxative, marketed under the all-too-descriptive name Purgen, was an immediate success. Shortly after its introduction in 1900, a host of copycat vanilla-flavored laxatives flooded the market.

Considering the popularity of Purgen® and its numerous imitators, it should come as no surprise that a fellow Hungarian pharmacist was responsible for the next innovation in laxatives. Max Kiss had immigrated to Brooklyn, NY, in 1905, bringing with him the idea of a chocolate-flavored phenolphthalein laxative. The original name for his brainchild, BoBo, was quickly rejected, when he learned this word was also vulgar street slang. In a Hungarian language newspaper, Kiss read about the political deadlock in his homeland. The term for this constitutional stalemate was “ex-lex.” Eureka! Kiss christened his invention Ex-Lax®, shorthand for Excellent Laxative.

### EXTRA! EXTRA! READ ALL ABOUT IT!

Ex-Lax® was introduced in 1906, the same year the Bureau of Chemistry was established. This precursor to the Food and Drug Administration had a much more limited scope than the Food and Drug Administration, but was, nonetheless, the first federal attempt to regulate the strength and purity of drugs. Even the Food and Drug Administration, with its broader charter and greater regulatory powers, did not bother examining old-time over-the-counter medicines like Ex-Lax®. Not until the 1990s did the National Institutes of Health National Toxicity Program finally take a peek at phenolphthalein. To the scientists’ surprise and the manufacturers’ consternation, the first round of tests showed that phenolphthalein was carcinogenic. A second round of testing confirmed the potential danger.

On August 29, 1997, the Food and Drug Administration proposed a ban on phenolphthalein. Recognizing that further resistance was futile, the next day the makers of Ex-Lax® voluntarily removed their product from store shelves. Ex-Lax® was reformulated, with senna taking the place of phenolphthalein. Given it was phenolphthalein that triggered the allergic reaction, fixed drug eruptions due to Ex-Lax® passed into history.\*

### REFERENCES

- 1 Mook WH. Erythema figuratum perstans. *J Cutan Dis.* 1917;35:635–645.

\*Speaking of historical footnotes, Dr. Fox’s patient was the first reported case of laxative-induced fixed drug eruption.

Private Practice, Fort Lauderdale, FL

Address for Correspondence: Mark Bernhardt, MD, Private Practice, 1601 East Broward Boulevard, Fort Lauderdale, FL 33301. E-mail: [cheesedb@aol.com](mailto:cheesedb@aol.com)

Presented by TSLMS

# MUSIC CITY SCALE

Symposium for Cosmetic Advances  
& Laser Education



13TH ANNUAL MEETING  
MAY 9-12, 2018

MUSIC CITY CENTER  
NASHVILLE, TN



## REGISTER NOW FOR THE 13TH ANNUAL MUSIC CITY SCALE MEETING

COURSE CO-DIRECTORS: BRIAN S. BIESMAN, MD & MICHAEL H. GOLD, MD

- Lasers 101
- Sessions on Laser Innovations and Laser Safety
- Injectables: Old and New
- Live Patient Demo's with Injectables & EBDs
- Innovations in Medical and Cosmetic Dermatology
- Symposia led by KOLs in the areas of:
  - Acne & Rosacea
  - Psoriasis
  - Eczema
- Skin Care/Cosmeceutical Trends
- Feminine Rejuvenation Update

WWW.TNLASERSOCIETY.COM

## CASE STUDY

Vesna Petronic-Rosic, MD, MSc, Section Editor

# Coccidioidomycosis

Matthew Laffer,<sup>1</sup> Lindsay Ackerman, MD<sup>2</sup>

A 23-year-old man presented with new-onset pruritic and painful urticarial lesions and targetoid erythematous plaques on both palms, the trunk, and the upper and lower extremities (Figure 1). Additionally, small pustules were discovered on the neck (Figure 2), and there with edematous erythematous vermillion lips with splaying onto the cutaneous lips without ulceration. The patient stated he had had a fever before the eruption, fatigue, chills, myalgias, and sore throat. A chest x-ray was obtained and showed bilateral infiltrates. Two 4-mm punch biopsies were performed on the left forearm and left side of the neck; a resulting section from the left forearm is shown in Figure 3. (SKINmed. 2018;16:51–53)

**H**istologic examination of the biopsy specimens revealed spongiotic dermatitis, one of the few patterns often seen in cutaneous eruptions in patients with pulmonary or systemic coccidioidomycosis. Periodic acid–Schiff staining was negative for fungal organisms.

A complete blood count with differential revealed a neutrophil leukocytosis, and results of a comprehensive metabolic panel were within normal limits. Samples were negative for *Mycoplasma pneumoniae* IgM antibody, and positive for *Coccidioides* antibody.

The only significant factor in the patient's past medical history was that previously he had suffered from herpes zoster. He stated that he was 12.5% Filipino, had been born and raised in Michigan, but had recently moved to Arizona.

The patient was treated with a 14-day course of 400 mg fluconazole orally and an oral steroid taper, and was also given triamcinolone acetonide 0.1% cream to apply twice a day, as needed. Within 1 month after completion of his medications, the pulmonary and cutaneous clinical manifestations had completely cleared.

Coccidioidomycosis (cocci) is a fungal disease that is prevalent in the southwest United States, northern Mexico, and parts of

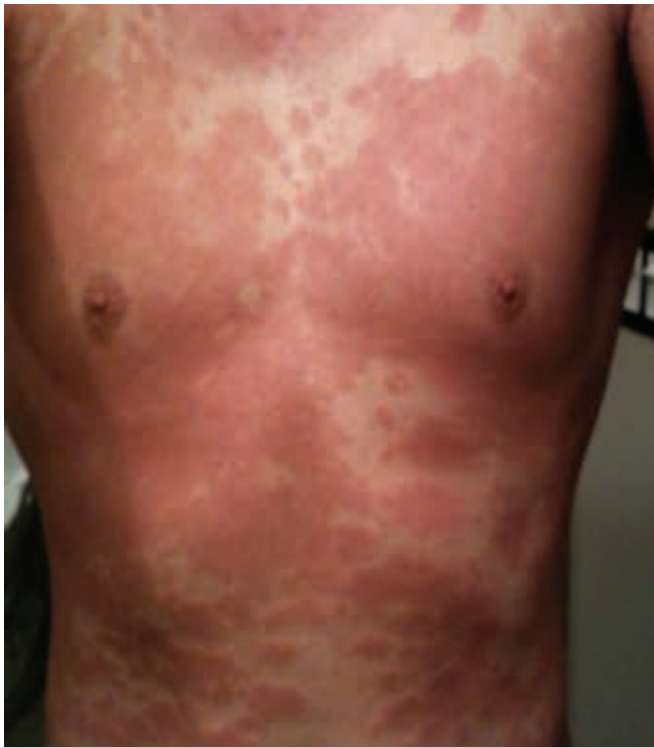Central and South America.<sup>1</sup> In the United States, the incidence is estimated to be 100,000 cases per year.<sup>2</sup> This disease is caused by the dimorphic, highly virulent pathogen *Coccidioides immitis*; infectious arthroconidia live in the soil and are inhaled.

Approximately 60% of patients have an asymptomatic infection, while most others have a self-limiting pulmonary infection.<sup>3,4</sup> Extrapulmonary complications vary, and the patient's ancestry and immune status may play a large role. In individuals of Caucasian ancestry, extrapulmonary complications are estimated to occur in as few as 0.5% of infections, whereas in individuals of African or Filipino ancestry, they may be significantly more common. Extrapulmonary complications may occur in as many as 50% of immunosuppressed patients, including those with AIDS or lymphoma, and those using high-dose corticosteroids. Extrapulmonary dissemination most frequently involves the skin, but commonly involves the meninges, bones, joints, and soft tissues.<sup>5</sup> Patients that present with clinical manifestations of an acute respiratory illness often display chest pain, cough and fever.<sup>6</sup>

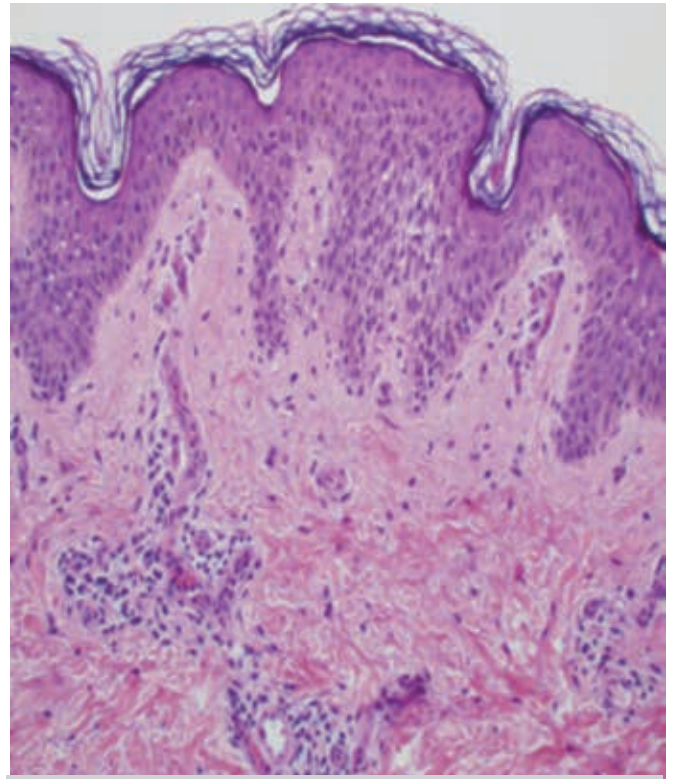
Cutaneous manifestations of coccidioidomycosis are variable, and can be classified as organism-specific or reactive. Organism-specific infections result from hematogenous spread to the skin in disseminated disease, or very rarely from primary cutaneous inoculation. These plaques often present as "lesions," morpho-

From the Macomb Center, St. John Macomb-Oakland Hospital, Warren, MI;<sup>1</sup> and Medical Dermatology Specialists, Phoenix, AZ<sup>2</sup>

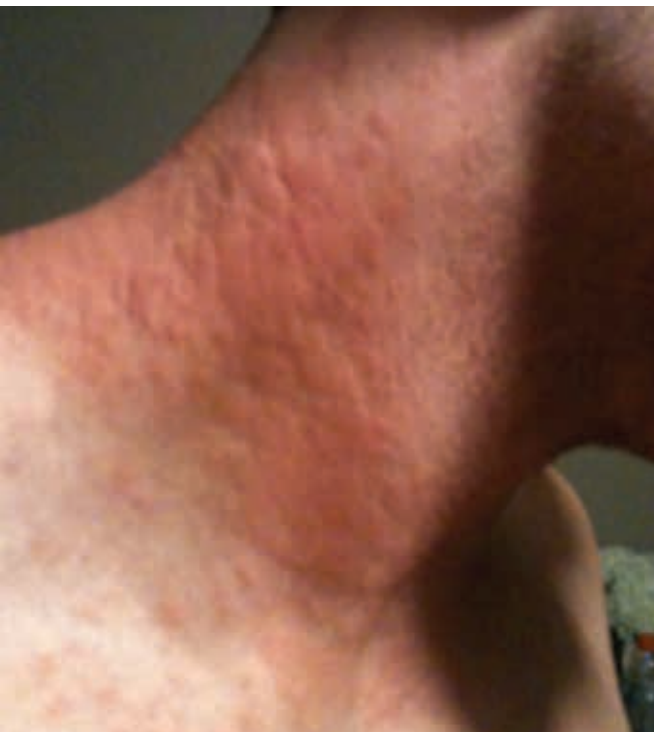Address for Correspondence: Lindsay Ackerman, MD, Medical Dermatology Specialists, 1331 North Seventh Street, Suite 250, Phoenix, AZ 85006 • E-mail: ackerman.lindsay@gmail.com



**Figure 1.** Coccidioidomycosis: pruritic and painful urticarial lesions and targetoid erythematous plaques on the chest and abdomen.



**Figure 3.** Coccidioidomycosis: 4-mm punch biopsy from the left forearm.



**Figure 2.** Coccidioidomycosis: small pustules on the neck.

logically represented as papules, nodules, abscesses, sinus tracts, or large verrucous plaques. The histopathology of a primary lesion demonstrates dense infiltrates of neutrophils, lymphocytes, and plasma cells, at times with necrosis, microabscess formation, or granulomas, with evidence of cocci spherules.<sup>8,9</sup>

Reactive cutaneous manifestations of cocci are clinically variable and can present as toxic erythema, erythema multiforme, morbilliform exanthems, erythema nodosum, and Sweet-like reactions.<sup>7</sup> Commonly, the histology of cutaneous reactions to cocci infections includes perivascular lymphocytic infiltrates with neutrophils and eosinophils in the dermis, and epidermal spongiosis that can be mild or very marked, causing basilar keratinocyte vacuolization.<sup>2</sup> Because the histology is variable, serologic tests and fungal cultures are helpful to confirm the diagnosis.

## CONCLUSIONS

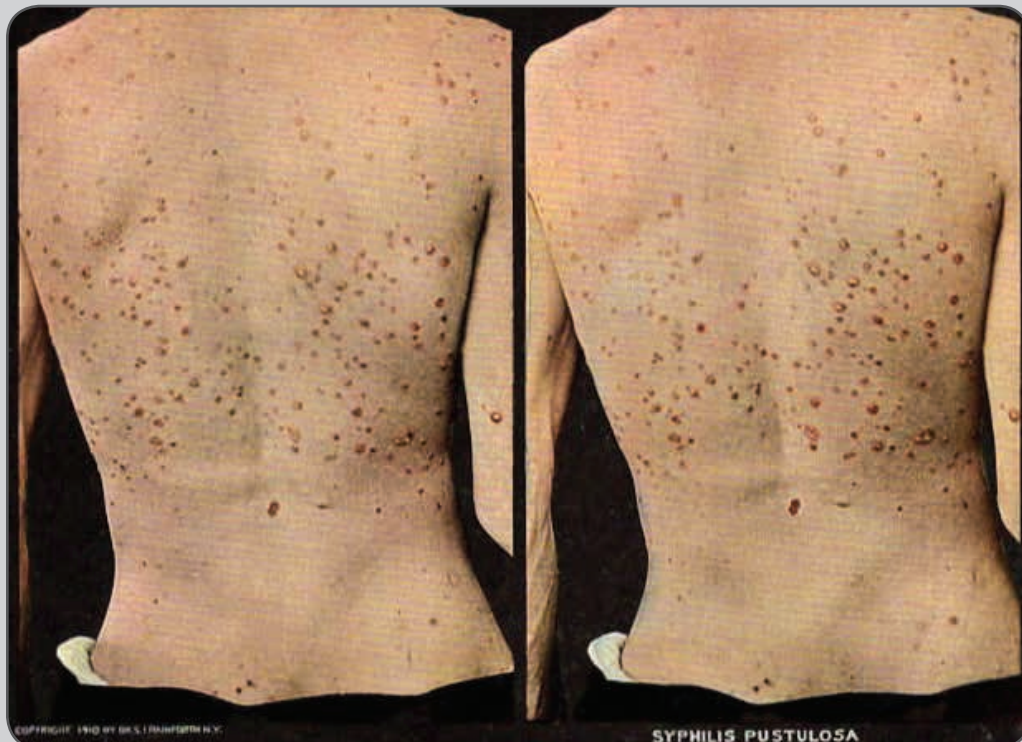Treatment of a coccidioidomycosis is dependent upon the extent of pulmonary compromise, the presence of dissemination, and underlying patient risk factors. Treatment for uncomplicated pulmonary cocci is controversial, whereas azole antifungals are used for severe pulmonary infections, disseminated disease, or infections occurring in immunocompromised individuals.<sup>2,5</sup>

## REFERENCES

- 1 Maddy K. The geographic distribution of *coccidioides immitis* and possible ecologic implications. *Ariz Med*. 1958;15:178–188.
- 2 DiCaudo DJ, Yiannias JA, Laman SD, Warschaw KE. The exanthem of acute pulmonary coccidioidomycosis: clinical and histopathologic features of 3 cases and review of the literature. *Arch Dermatol*. 2006;142:744–746.
- 3 Bologna J, Jorizzo J, Schaffer J. *Dermatology*. 2nd ed. Philadelphia: Mosby Elsevier; 2008:Chapter 76.
- 4 Carpenter J, Feldman JS, Leyva WH, DiCaudo DJ. Clinical and pathologic characteristics of disseminated cutaneous coccidioidomycosis. *J Am Acad Dermatol*. 2010;62:831–837.
- 5 Galgiani JN, Ampel NM, Blair JE, et al. Coccidioidomycosis. *Clin Infect Dis*. 2005;41:1217–1223.
- 6 Kim A, Parker S. Coccidioidomycosis: Case report and update on diagnosis and management. *J Am Acad Dermatol*. 2002;46:743–747.
- 7 DiCaudo, D. Coccidioidomycosis: A review and update. *J Am Acad Dermatol*. 2006;55:929–942.
- 8 Chang A, Tung RC, McGillis TS, Bergfeld WF, Taylor JS. Primary cutaneous coccidioidomycosis. *J Am Acad Dermatol*. 2003;49:221–228.
- 9 Quimby SR, Connolly SM, Winkelmann RK, Smilack JD. Clinicopathologic spectrum of specific cutaneous lesions of disseminated coccidioidomycosis. *J Am Acad Dermatol*. 1992;26:79–85.

## HISTORICAL DIAGNOSIS AND TREATMENT

*Diagnosis and treatments have advanced over the past century. This feature depicts conditions from a collection of stereoscopic cards published in 1910 by The Stereoscopic Skin Clinic by, Dr S. I. Rainforth.*



(Continued on page 75)



13<sup>TH</sup> WORLD CONGRESS OF  
**COSMETIC  
DERMATOLOGY**

Sponsored by  
the International  
Academy  
of Cosmetic  
Dermatology  
(IACD)

**Dubrovnik**  
Croatia  
28<sup>th</sup> June - 1<sup>st</sup> July  
**2018**

[www.wcocddubrovnik2018.org](http://www.wcocddubrovnik2018.org)





## CASE STUDY

# Tuberous Sclerosis Complex: A Classic Presentation

Virendra N. Sehgal, MD, FNASc, FAMS, FRAS (Lond);<sup>1</sup> Navjeeven Singh, MD;<sup>2</sup>  
 Sonal Sharma, MD;<sup>2</sup> Jolly Rohatgi, MS;<sup>3</sup> Rakesh Oberai, MD;<sup>4</sup>  
 Kingshuk Chatterjee, DNB, MNAMs<sup>5</sup>

An 11-year-old girl presented with an insidiously evolving, reddish-brown, small, hard, elevated lesion, occupying the midsection of her face, which had been present since early childhood. There were also a few small white spots over the trunk. There was no history of seizures or visual deficit, and no burning on exposure to sunlight. There were no known congenital defect noted at birth, and her parents were nonconsanguineous. There was no significant family history. There were numerous 2- to 4-mm reddish-brown papules located symmetrically on the nose, nasolabial folds, and cheeks (Figure 1A). In addition, there was an uneven 3-cm plaque in the lumbosacral region that resembled orange peel—a shagreen patch (Figure 1B). There were also two well-defined, 5- to 10-mm, hypomelanotic, ivory-white macule(s) with irregular margins (Figure 1C). The buccal mucosa and nails were unremarkable, and indirect ophthalmoscopic and slit-lamp examination of the eye was normal. Laboratory studies were unremarkable. Ultrasonography of the abdomen was normal, as were abdominal and chest x-rays. (*SKINmed*. 2018;16:55–58)

**H**ematoxylin and eosin–stained sections prepared from the hard plaque on the face revealed a normal-looking epidermis, small pilosebaceous units, and evidence of increased dermal collagen (Figure 2A). At higher magnification, “onion-peel”-like concentric bands of collagen were seen surrounding abortive hair follicles (Figure 2B). Concentric bands of fibrosis were also seen around some of the eccrine ducts (Figure 2C), appearing to constrict their lumina. The small sebaceous glands in the dermis were surrounded by dense collagen bands.

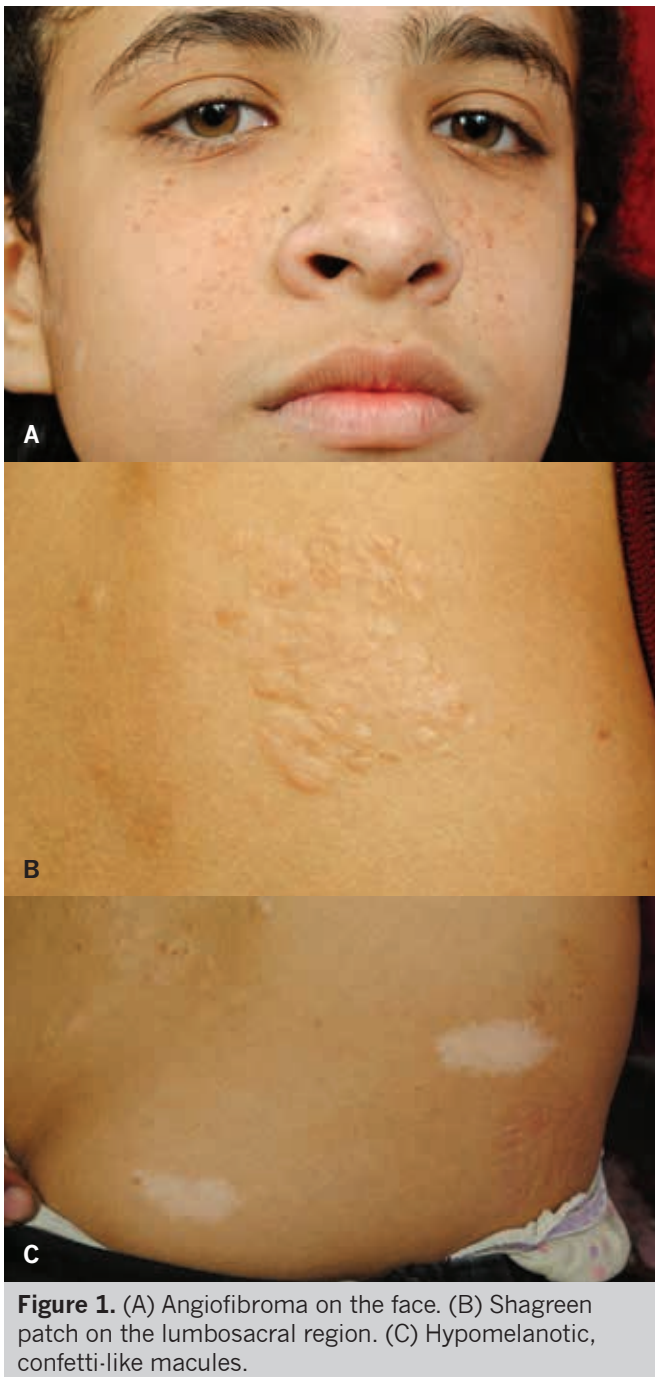Sections from the plaque on the back showed a dome-shaped elevation of the epidermis caused by dense fibrous tissue, and a paucity of dermal appendages and vasculature. Concentric bands of collagen, surrounding small, congested blood vessels, were also seen in the dermis.

## MAGNETIC RESONANCE IMAGING (MRI)

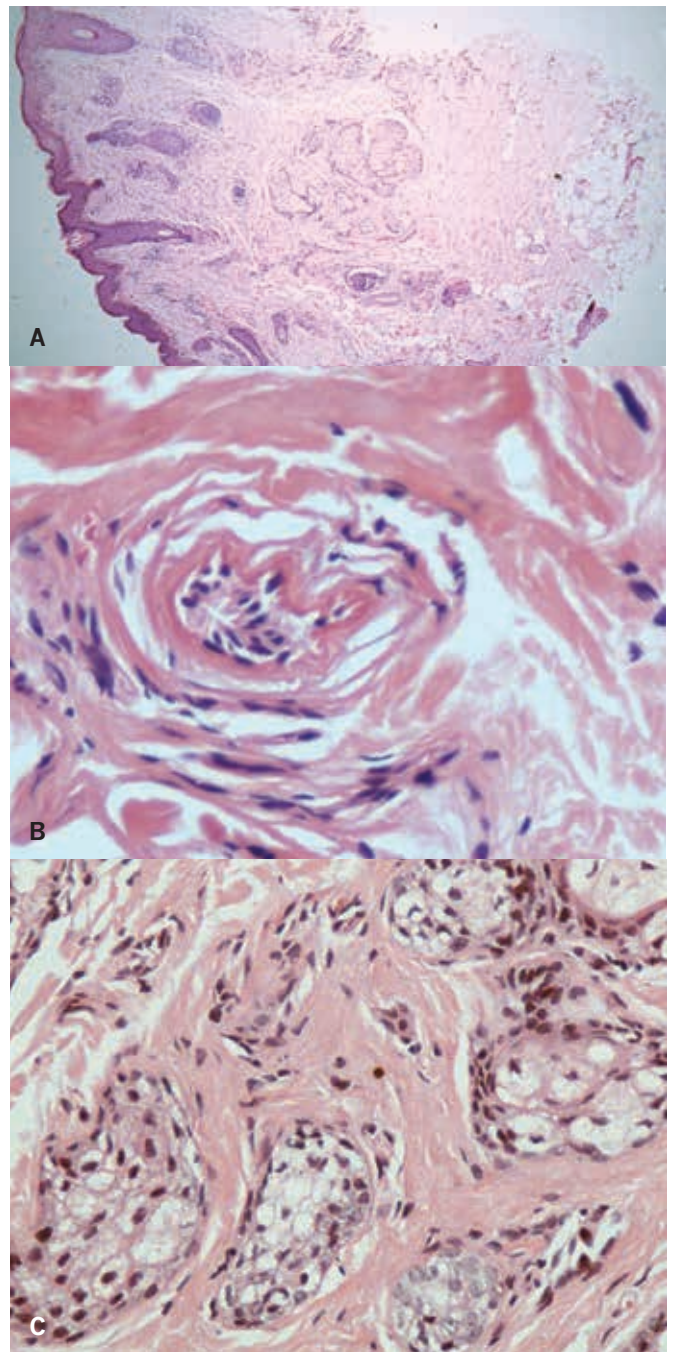
MRI of the brain was performed on a 1.5 T MRI scanner (Signa HDxt; GE Medical Systems, Milwaukee, WI) using turbo spin-echo T1-weighted, T2-weighted, and fluid-attenuated inversion recovery (FLAIR) sequences in the axial plane. This showed subependymal nodules along the walls of the lateral ventricles, which appeared hyperintense on T1- and T2-weighted MRI (Figure 3). There were also small focal lesions in the left frontal lobe cortex (Figure 4) and left cerebellum (Figure 5), which appeared hyperintense on T2-weighted and FLAIR images, and isointense to hypointense on T1-weighted images (Figure 5). In addition, bilateral bandlike hyperintense lesions were seen in the deep white matter on FLAIR images. An extra-axial cystic lesion was also seen in the left temporal region, appearing hypointense on FLAIR and hyperintense on T2-weighted images. The orbits were unremarkable.

From the Department of Dermato Venereology (Skin/VD) Center, Sehgal Nursing Home, Panchwati, Delhi;<sup>1</sup> the Department of Pathology<sup>2</sup> and the Department of Ophthalmology,<sup>3</sup> University College of Medical Sciences and Associated Guru Teg Bahadur Hospital, Shahadra, Delhi; the Department of Radiology, Sri Balaji Action Medical Institute Paschim Vihar, New Delhi;<sup>4</sup> and the Department of Dermatology, Bankura Sammilani Medical College, Bankura, West Bengal,<sup>5</sup> India

Address for Correspondence: Virendra N. Sehgal, MD, FNASc, FAMS, FRAS (Lond), Dermato Venereology (Skin/VD) Center, Sehgal Nursing Home, A/6 Panchwati, Delhi 110 033, India • E-mail: drsehgal@ndf.vsnl.net.in, sehgalvn@yahoo.co.in



**Figure 1.** (A) Angiofibroma on the face. (B) Shagreen patch on the lumbosacral region. (C) Hypomelanotic, confetti-like macules.



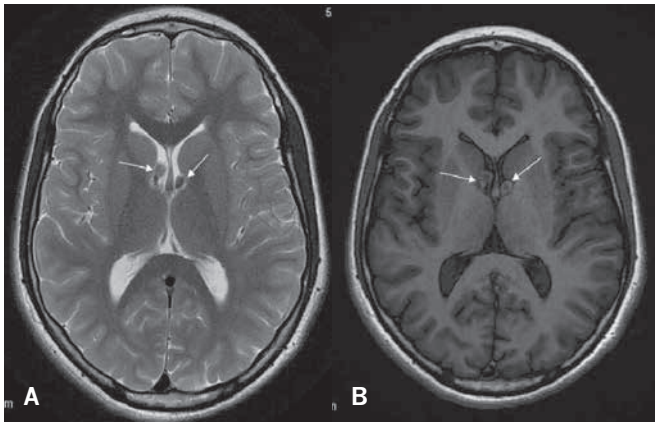
**Figure 2.** (A) Skin section, exhibiting a normal epidermis and small pilosebaceous units (hematoxylin and eosin stain, magnification  $\times 40$ ). (B) “Onion-peel”-like concentric bands of collagen surrounding a hair follicle (hematoxylin and eosin stain, magnification  $\times 200$ ). (C) Eccrine duct surrounded by concentric fibrosis (hematoxylin and eosin stain, magnification  $\times 400$ ).

Ultrasonography of the abdomen, including the kidneys and liver, was normal.

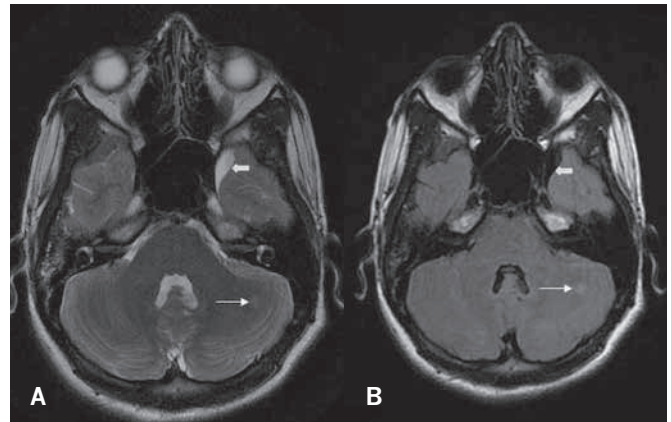
## DISCUSSION

Tuberous sclerosis is a genetic disorder in which cellular differentiation and proliferation results in hamartoma formation in the skin, brain, eye, kidney, and heart.<sup>1,2</sup> Friedrich Daniel von

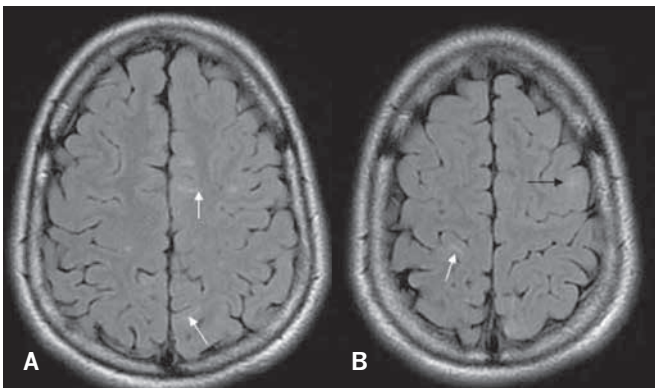
Recklinghausen (1833–1910)<sup>3</sup> provided the initial description in 1862, while Désiré-Magloire Bourneville<sup>4</sup> (1840–1909) coined the term *sclérose tubéreuse*, from which the current name



**Figure 3.** (A) Axial T2-weighted image demonstrating hyperintense subependymal nodules (arrows) along the lateral ventricles. (B) On axial T1-weighted imaging, the nodules appeared hyperintense with central hypointensity (arrows).



**Figure 5.** Axial T2-weighted image showing a focal hyperintense lesion in the left cerebellum (thin arrow) and an extra-axial hyperintense lesion in the left temporal region (thick arrow). (B) On axial fluid-attenuated inversion recovery images, the left cerebellar lesion appeared hyperintense (thin arrow), and the extra-axial left temporal lesion appeared hypointense (thick arrow).



**Figure 4.** Axial fluid-attenuated inversion recovery images demonstrating hyperintense linear radial bands in the deep white matter bilaterally (white arrows) and a focal hyperintense lesion in the left parietal cortex (black arrow).

**Table. Tuberous Sclerosis Complex: Criteria for Diagnosis**

MAJOR FEATURES	MINOR FEATURES
<b>Skin manifestations</b> <ul style="list-style-type: none"> <li>• Facial angiofibromas</li> <li>• Ungual fibromas</li> <li>• More than three hypomelanotic macules</li> <li>• Shagreen patches</li> </ul>	<ul style="list-style-type: none"> <li>• Multiple randomly distributed pits in dental enamel</li> <li>• Rectal polyps</li> <li>• Bone cysts</li> <li>• Cerebral white matter migration abnormalities on brain imaging</li> <li>• Gingival fibromas</li> <li>• Nonrenal hamartomas</li> <li>• Retinal achromic patches</li> <li>• Confetti skin lesions</li> <li>• Multiple renal cysts</li> </ul>
<b>Brain</b> <ul style="list-style-type: none"> <li>• Cortical tubers</li> <li>• Subependymal nodules</li> <li>• Subependymal giant cell astrocytomas</li> </ul>	
<b>Eye lesions</b> <ul style="list-style-type: none"> <li>• Multiple retinal nodular hamartomas</li> </ul>	
<b>Tumors in other organs</b> <ul style="list-style-type: none"> <li>• Cardiac rhabdomyomas</li> <li>• Lymphangiomyomatosis</li> <li>• Renal angiomyolipomas</li> </ul>	

To avoid “double-counting” because central nervous system lesions can also cause seizures, the criteria do not include seizures/intellectual disability.

is derived. The clinical triad of epilepsy, low intelligence, and adenoma sebaceum, the *epiloia*, was described by Sherlock.<sup>5</sup> The term *tuberous sclerosis complex* (TSC)<sup>1</sup> is now widely used, emphasizing its variegated nature. The entity is rare and has been rarely reported,<sup>6,7</sup> as was elaborated upon by the Tuberous Sclerosis Alliance and the National Institute of Health (Table).<sup>8</sup>

Our patient had facial angiofibromas, a shagreen patch, and hypomelanotic, confetti-like<sup>9,10</sup> skin lesions as a few of its salient cutaneous manifestations, which was adequate to consider the diagnosis of TSC as it conformed to the major features of this condition (see above).

The microscopic pathology<sup>1,11</sup> was significant enough to warrant recommending a skin biopsy before obtaining an MRI scan. Multiple high-signal MRI lesions are characteristic of TSC,<sup>12</sup> corresponding to the hamartomas and gliotic area seen patho-

logically. MRI may be useful in predicting the eventual clinical severity in younger children with newly diagnosed TSC.

Cortical tubers, subependymal nodules, and white matter lesions are commonly encountered in TSC. Less common manifestations include cerebellar atrophy, dysgenesis of the corpus callosum, Chiari malformations, arachnoid cysts, and infarctions due to occlusive vascular disorders. MRI is the most sensitive modality for their detection.<sup>13,14</sup>

Cortical tubers, subependymal nodules, white matter lesions, and a left temporal arachnoid cyst were seen in the present case. The cortical tubers showed increased signal intensity on T2-weighted and decreased signal intensity on T1-weighted sequences.

On MRI, subependymal nodules are isointense/hyperintense on T2-weighted images and hyperintense on T1-weighted images, and may also demonstrate central low T2 signal with a surrounding hyperintense rim. Subependymal nodules typically measure less than 1 cm but may grow over time, giving rise to subependymal giant cell astrocytomas, which are commonly located at foramen of Monro, and can cause acute obstructive hydrocephalus. They are heterogenous on MRI, contain calcification, and show intense unhomogeneous enhancement. Superficial white matter abnormalities—radial white matter bands, which are lines of arrested neuronal migration—appear as radiating bright lines on T2-weighted and FLAIR images. White matter cystic lesions may also occur.

MRI, therefore, plays an important role in arriving at the correct diagnosis of TSC, especially in asymptomatic patients, to determine the presence and extent of organ involvement. Follow-up MRI should be carried out for evaluation of the lesions and early detection of associated complications.

## CONCLUSIONS

Although TSC is a well-known genetic disorder, there are only sporadic reports describing it. Slowly evolving angiofibromas affecting the mid-facial region, a shagreen patch, and hypomelanotic, confetti-like lesions should arouse suspicion. The clinical diagnosis should be supplemented by histopathology. Ultimate-

ly, carrying out an MRI to define the neurologic findings, plus a slit-lamp examination, is recommended.

## REFERENCES

- 1 Kacerovska D, Kerl K, Michal M, et al. Giant angiofibromas in tuberous sclerosis complex: A possible role for localized lymphedema in their pathogenesis. *J Am Acad Dermatol*. 2012;67:1319–1326.
- 2 Schwartz RA, Fernández G, Kotulska K, et al. Tuberous sclerosis complex: Advances in diagnosis, genetics, and management. *J Am Acad Dermatol*. 2007;57:189–202.
- 3 von Recklinghausen F. Ein Herz von einem Neugeborene welches mehrere theils nach aussen, theils nach den Hohlen prominirende Tumoren (Myomen) trug. *Monatschr Geburtsheilkd*. 1862;20:1–2.
- 4 Bourneville DM. Contribution a l'étude de l'idiotie: Sclérose tubéreuse des circonvolutions cérébrale: Idiote et épilepsie hemiplegique. *Arch Neurol*. 1880;1:81–91.
- 5 Sherlock EB. *The Feeble-minded: A Guide to Study and Practice*. London: Macmillan; 1911:235–247.
- 6 Sehgal VN, Sehgal N. Cutaneous manifestations of tuberous sclerosis. *Indian J Dermatol Venereol Leprol*. 1969;35:198–199.
- 7 Hake S. Cutaneous manifestations of tuberous sclerosis. *Ochsner J*. 2010;10:200–204.
- 8 Maria BL, Deidrick KM, Roach ES, et al. Tuberous sclerosis complex: Pathogenesis, diagnosis, strategies, therapies, and future research directions. *J Child Neurol*. 2004;19:632–642.
- 9 Sehgal VN, Sharma S, Verma P, et al. Idiopathic confetti-like leukoderma with unusual presentation. *Am J Dermatopathol*. 2012;34:117–121.
- 10 Sehgal VN, Srivastava G. Hereditary hypo/de-pigmented dermatoses: An overview. *Int J Dermatol*. 2008;47:1041–1050.
- 11 Torrelo A, Hadj-Rabia S, Colmenero I, et al. Folliculocystic and collagen hamartoma of tuberous sclerosis complex. *J Am Acad Dermatol*. 2012;66:617–621.
- 12 Roach ES, Williams DP, Laster DW. Magnetic resonance imaging in tuberous sclerosis. *Arch Neurol*. 1987;44:301–303.
- 13 Radhakrishnan R, Verma S. Clinically relevant imaging in tuberous sclerosis. *J Clin Imaging Sci*. 2011;1:39.
- 14 Umeoka S, Koyama T, Miki Y, et al. Pictorial review of tuberous sclerosis in various organs. *Radiographics*. 2008;28:e32.

# Vegas Cosmetic Surgery



Register  
Early &  
Save!

**June 6 - 10, 2018**  
Bellagio, Las Vegas

**HOLD THE DATE!**

America's Premiere Multispecialty Symposium

[www.VegasCosmeticSurgery.com](http://www.VegasCosmeticSurgery.com)



## CASE STUDY

# Pemphigus Vegetans Confined to the Face and Scalp

Anissa Zaouak, MD;<sup>1</sup> Houda Hammami, MD;<sup>1</sup> Mariem Belhaj Salah, MD;<sup>2</sup>  
Achraf Debbiche, MD;<sup>2</sup> Samy Fenniche, MD<sup>1</sup>

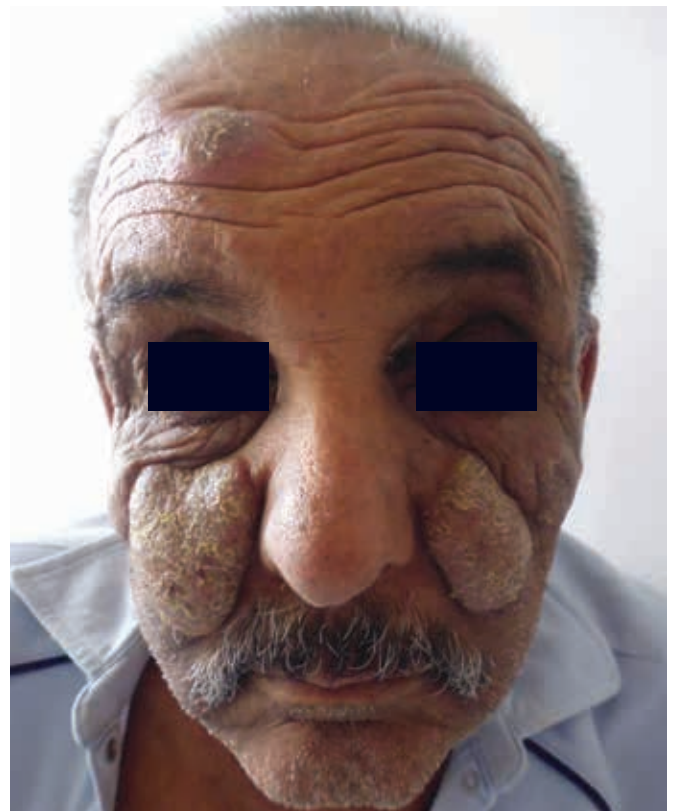A 58-year-old man presented to our department with multiple chronic vegetant plaques on the face and scalp that had been present for 4 months. The plaques were well-defined hypertrophic areas, measuring between 3 cm × 3 cm and 3 cm × 4 cm, that were located mainly on the face symmetrically and on the forehead (Figure 1). The patient did not report itching or pain. There were also dry, crusty, well-defined plaques on the scalp. No other lesions were present on the skin or mucous membranes. (*SKINmed*. 2018;16:60–61)

**A**cutaneous biopsy showed marked epidermal papillomatosis, acanthosis, and hyperkeratosis with diffuse suprabasal cleavage. The dermis showed heavy infiltration by lymphocytes and eosinophils (Figure 2). Direct immunofluorescence demonstrated epidermic intercellular deposits of immunoglobulin G. Antibodies against desmoglein 3 were also present.

Clinical, histologic and immunopathologic findings allowed us to make a diagnosis of pemphigus vegetans confined to the face and scalp. We initiated prednisone 1.25 mg/kg per day with azathioprine 50 mg per day. After 4 months, there was complete resolution of the vegetating plaques. At the time of writing, the patient was still receiving maintenance therapy.

## DISCUSSION

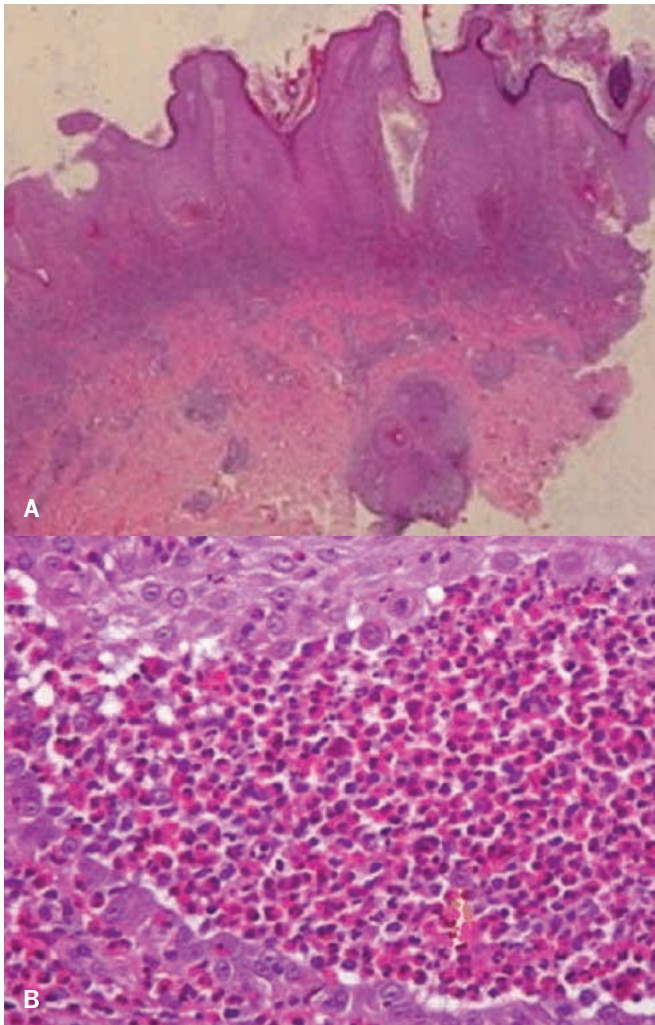
Pemphigus vegetans is a rare variant of pemphigus vulgaris, characterized by chronic vegetating erosions primarily in the flexures. It was first described by Isador Neumann (1832–1906) in 1876.<sup>1,2</sup> It usually presents as heaped-up, cauliflower-like vegetating plaques in the flexures. Although most lesions are typically located in intertriginous spaces, any area of the integument can be affected. Involvement of the scalp, soles, genitalia, and nails has been described.<sup>3</sup>



**Figure 1.** Bilateral verrucous and scaly plaques on the cheek and forehead.

From the Department of Dermatology<sup>1</sup> and the Department of Anatomopathology,<sup>2</sup> Habib Thameur Hospital, Tunis, Tunisia  
Address for Correspondence: Anissa Zaouak, MD, 8 Street Ali Ben Ayed, Montfleury 1008, Tunis, Tunisia

• E-mail: anissa\_zauouak@yahoo.fr



**Figure 2.** (A) Suprabasal intraepidermal acantholysis with papillomatosis (hematoxylin and eosin stain, magnification  $\times 40$ ). (B) Intraepidermal microabscesses consisting of eosinophils and neutrophils (hematoxylin and eosin stain, magnification  $\times 100$ ).

We report here a patient with the unusual presentation of dry vegetating lesions confined to the face and scalp. In nonintertriginous locations, as in our patient, the vegetating plaques dry out, evolving into warty, fissured, painful plaques that, on the face, simulate seborrheic keratoses; hence, it is classified as dry pemphigus vegetans<sup>4</sup>

The diagnosis of pemphigus vegetans is based on clinical manifestations and confirmed by histology. Lesional histopathol-

ogy typically shows papillomatous, verrucous, or pseudoepitheliomatous hyperplasia. Suprabasal acantholysis can be masked by an exuberant proliferation of involved epidermis. Intraepidermal microabscesses consisting of eosinophils and neutrophils are often seen. It is associated with antibodies against desmogleins, mainly desmoglein 3. In this rare type of pemphigus, it appears that the different pathogenicity of the autoantibodies plays a role in the peculiar clinical presentation of affected patients.<sup>4</sup>

The main clinical differential diagnosis of facial pemphigus vegetans with similar clinical manifestations is seborrheic keratosis, but this was ruled out here by the skin biopsy. In addition, an incorrect diagnosis of pemphigus erythematosus could have been made due to the localization of the crusty plaques in the seborrheic areas. This diagnosis was also ruled out by histologic findings consistent with suprabasal acantholysis.

The treatment of pemphigus vegetans is the same as for pemphigus vulgaris. Systemic corticosteroids are the mainstay of therapy and should be combined with immunosuppressive therapy such as azathioprine, as in our patient. The overall prognosis is good, with a low mortality rate. Patients with Neumann type pemphigus vegetans may show a severe disease course similar to that of pemphigus vulgaris.<sup>4</sup>

## CONCLUSIONS

The present case was unusual, as the lesions were nonflexural in distribution, and the oral mucosa was not involved. A high index of suspicion is required to diagnose pemphigus vegetans at nonintertriginous sites.

## REFERENCES

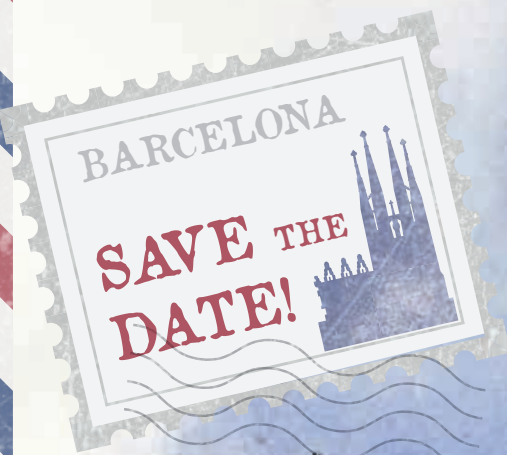- 1 Wei J, He CD, Wei HC, et al. Facial pemphigus vegetans. *J Dermatol.* 2011;38:615–618.
- 2 Khullar G, De D, Narang T, Saikia UN, Handa S. Pemphigus vegetans localized to unusual sites. *Indian J Dermatol Venereol Leprol.* 2015;81:509–511.
- 3 Danopoulou I, Stavropoulos P, Stratigos A, et al. Pemphigus vegetans confined to the scalp. *Int J Dermatol.* 2006;45:1008–1009.
- 4 Ruocco V, Ruocco E, Lo Schiavo A, et al. Pemphigus: Etiology, pathogenesis and inducing or triggering factors: Facts and controversies. *Clin Dermatol.* 2013;31:374–381.

9<sup>TH</sup> 5-CONTINENT CONGRESS

# BARCELONA

AUGUST 30 - SEPTEMBER 2

# 2018



– THE WORLD'S LEADING CONFERENCE ON –  
EMERGING TECHNOLOGIES | ENERGY-BASED DEVICES | NEUROMODULATORS  
COSMECEUTICALS | FILLERS | AESTHETIC GYNECOLOGY

[WWW.5-CC.COM](http://WWW.5-CC.COM)



## CASE STUDY

# Disseminated Cutaneous Rhinosporidiosis

Neel Prabha, MBBS, MD;<sup>1</sup> Ripudaman Arora, MBBS, MS;<sup>2</sup> Namrata Chhabra, MBBS, MD;<sup>1</sup> Williams Joseph, MS;<sup>2</sup> Vandita Yogendra Singh, MBBS, MD;<sup>3</sup> Satish Suresh Satpute, MBBS, MS;<sup>2</sup> Nitin M. Nagarkar, MBBS, MS<sup>2</sup>

A 41-year-old man from the state of Chhattisgarh, India, had a previous history of nasopharyngeal rhinosporidiosis for 27 years, for which he had surgical intervention seven times, most recently endoscopically 2 months earlier. For the last 8 months, he had noticed skin lesions on the shoulders and forehead. Of interest was a history of bathing in ponds as a child. Examination revealed a soft, skin-colored, strawberry-shaped papule on the forehead (Figure 1A), a papule with a hemorrhagic crust on the left shoulder (Figure 1B), and a crusted friable plaque on the right shoulder (Figure 1C). Endoscopy revealed a 1 cm × 1 cm red polypoidal mass on the lateral wall of the nasopharynx. A diagnosis of disseminated cutaneous rhinosporidiosis with nasal-nasopharyngeal rhinosporidiosis was considered. (*SKINmed*. 2018;16:63–65)

Routine blood studies and HIV screening were negative, as were a chest X-ray, a computed tomography scan of the brain, and an abdominal ultrasound. The lesions were surgically excised with electrodesiccation of the bases. Histopathologic examination of the skin lesions showed multiple sporangia and spores with morphologic features of *Rhinosporidium* species along with foreign body giant cells in the dermis (Figure 2). When a final diagnosis of nasal-nasopharyngeal rhinosporidiosis with cutaneous dissemination had been made, the patient was started on oral dapsone (100 mg per day) for 3 months. He improved and did not show any recurrence of the nasal or cutaneous lesions.

## DISCUSSION

Rhinosporidiosis is a chronic recurrent granulomatous disease of humans and animals, caused by *Rhinosporidium seeberi*. It is endemic in some areas of Asia, such as south India and Sri Lanka, but infections have been reported in the Americas, Europe, and Africa. In India, the disease is endemic in Chhattisgarh, Tamilnadu, Kerala, parts of Orissa, and eastern Madhya Pradesh. The causative organism was first reported by Malbran but later described by Guillermo Seeber, both from Buenos Aires, Argentina, giving it its name, *R. seeberi*.

The taxonomy of the causative agent of rhinosporidiosis has always been controversial. Seeber considered the sporangium

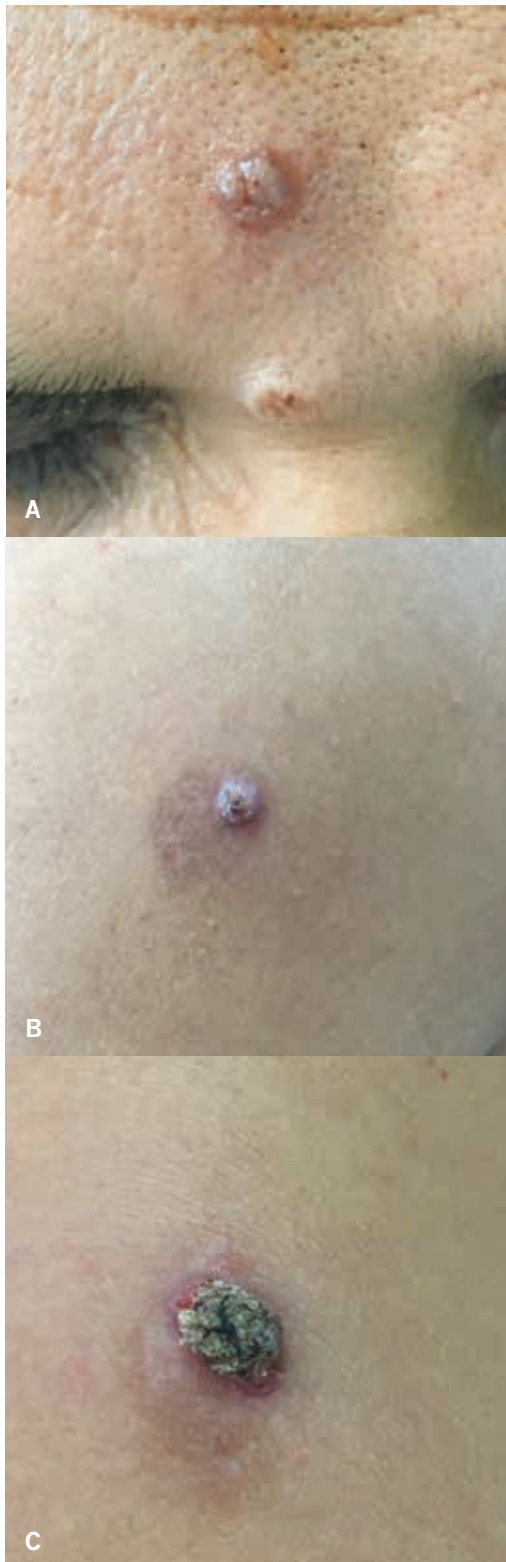of *R. seeberi* to be a sporozoon. Although the agent was considered to be a fungus, it was interpreted as a protozoan parasite, a cyanobacterium, and a carbohydrate waste product. It has been proposed that the organism should be considered in a new eukaryotic group of protists known as Mesomycetozoa.<sup>1</sup> Others have agreed with the concept of a novel clade of aquatic protistan parasites named Ichthyosporea.<sup>2</sup> The causative agent of rhinosporidiosis may well be the cyanobacterium *Microcystis aeruginosa*, isolated from clinical samples as well as from samples of water in which patients have been bathing.<sup>3</sup>

The life cycle of the parasite is complicated. The mature forms of the organism, known as sporangia, contain multiple sporangiospores. The trophocytes, the immature forms of *R. seeberi*, are smaller and thinner than sporangia and do not contain endospores. Sporangiospores are released at maturity and thereafter develop into trophocytes. The disease is possibly transmitted to humans by direct contact with spores through dust, infected clothing, or fingers, and by swimming in stagnant waters. Although a large number of people living in endemic areas bathe in common ponds, only a few develop the disease. This indicates the existence of predisposing factors in the host.

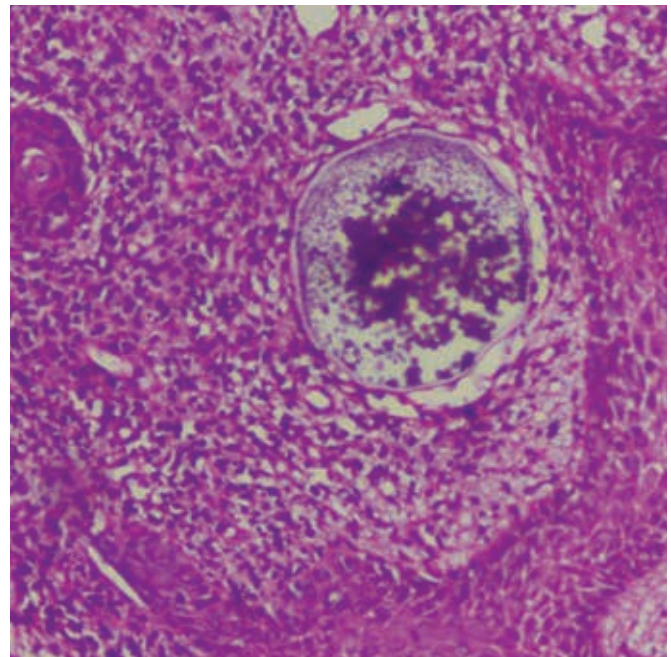
Blood group studies indicate that rhinosporidiosis is common in patients with group O and group AB blood;<sup>4</sup> however, the blood group distribution is too variable to draw any conclusion.<sup>5</sup> Goihman-Yahr has postulated that a lack of digestive capacity of

From the Department of Dermatology, Venereology and Leprology,<sup>1</sup> Department of ENT and HNS,<sup>2</sup> and Department of Pathology,<sup>3</sup> All India Institute of Medical Sciences, Tatibandh, Raipur, Chhattisgarh, India

Address for Correspondence: Ripudaman Arora, MBBS, MS, Department of ENT and HNS, All India Institute of Medical Sciences, GE Road, Tatibandh, Raipur, Chhattisgarh, India • E-mail: neelripu@gmail.com



**Figure 1.** (A) Skin-colored, strawberry-shaped papule on the forehead. (B) Papule with hemorrhagic crust on the left shoulder. (C) Crusted friable plaque on the right shoulder.



**Figure 2.** Histopathology showing sporangium with endospores in the dermis (hematoxylin and eosin, magnification  $\times 100$ ).

phagocytes from affected patients may explain why only a few individuals acquire the infection.<sup>6</sup>

Clinically, morphology of rhinosporidiosis lesions is characterized by the development of pedunculated and sessile polypoid lesions on the mucosa of the nose, eyes, and larynx, and very rarely on other parts of the body, such as the skin, viscera, and brain. Disseminated cutaneous lesions are very rare and are generally associated with mucosal lesions. Cutaneous lesions without mucosal involvement are extremely rare.<sup>7,8</sup>

Three main types of lesions appear on the skin:

1. satellite lesions around the nose in cases of nasal rhinosporidiosis;
2. generalized skin involvement with or without nasal involvement caused by hematogenous dissemination;
3. primary cutaneous lesions, which may occur by direct inoculation of the organism into the skin<sup>7</sup>

Rhinosporidiosis has a multifaceted presentation on the skin. Cutaneous lesions have been reported as pedunculated or sessile growths, verruca vulgaris-like lesions, friable nodular lesions, subcutaneous swellings, furunculoid lesions, cutaneous horns, shiny globular swellings, cutaneous ulcerations, and cystic swellings. Development of a cutaneous lesion may be an indication of early

dissemination, and a thorough search should be made to exclude systemic involvement; our patient did not reveal any systemic lesions. The various clinical differential diagnoses include verrucae vulgaris, verrucous tuberculosis, and granuloma pyogenicum.<sup>7</sup>

As the organism cannot be grown in culture, histopathology is the gold standard.<sup>9</sup> Giemsa imprinted smears and a fine needle aspirate with 10% KOH examination are also helpful.<sup>7</sup> A biopsy may reveal a hyperplastic epithelium with a chronic inflammatory cell infiltrate composed of plasma cells and lymphocytes along with foreign body giant cells. Characteristic sporangia in various stages of maturation are seen as globular cysts of various sizes (50 to 1000  $\mu\text{m}$  in diameter), lined by a well-defined wall and containing numerous endospores of diameter 5 to 10  $\mu\text{m}$ . Sporangia and endospores stain positively with various special stains such as Gomori methenamine silver, periodic acid–Schiff, mucicarmine, Grocott stain, and hematoxylin and eosin.<sup>10</sup> The periodic acid–Schiff stain is helpful in discriminating between endospores and epithelial cells, especially from the nasopharynx, as the endospores stain markedly magenta, while the epithelial cells are periodic acid–Schiff–negative.<sup>9</sup>

Mucicarmine stain is particularly helpful in differentiating *Coccidioides immitis*, as sporangia and spores of this organism do not stain positively. Coccidiomycotic lesions can cause confusion with rhinosporidiosis during cytologic as well as histopathologic evaluation, as the former has similar mature stages represented by large, thick-walled spherical structures containing endospores. Distinction can also be made by hematoxylin and eosin stain as the intrasporangial endospores of *R. seeberi* are larger and more numerous in comparison to those of *C. immitis*, and *C. immitis* can be cultured whereas *R. seeberi* cannot.<sup>10</sup>

Spontaneous regression of rhinosporidial growths has been noted in animals and in humans but is rare; therefore, medical and/or surgical intervention is necessary. Surgical removal and electrodesiccation are the treatments of choice. Adjuvant medical therapies, such as ketoconazole, amphotericin B, trimethoprim-sulfadiazine, and sodium stibogluconate have been tried, with varied success.<sup>11</sup> Data on antimicrobial drug resistance in *R. seeberi* are lacking. The strains obtained from human and animal rhinosporidiosis have shown genetic variations that might explain the variation of responses to some drugs.<sup>11</sup>

The only drug that appears to have clinical promise in treatment is dapsone. One study suggested that prolonged use of dapsone (100 mg/day for several months) may help prevent disease recurrence.<sup>12</sup> It arrests the maturation of sporangia and promotes fibrosis in the stroma when used as an adjunct to

surgery. It could be expected that presurgical dapsone would minimize the hemorrhage by its promotion of fibrosis, as well as preventing the colonization and infection of new sites after the release of endospores from surgically traumatized lesions.<sup>11</sup> Postoperative use of dapsone has been reported to minimize or prevent recurrence.<sup>13</sup>

## CONCLUSIONS

Our patient, who had recurrent nasopharyngeal lesions, underwent multiple endoscopic surgeries presented with multiple disseminated cutaneous lesions possibly with hematogenous spread.

## REFERENCES

- Herr RA, Ajello L, Taylor JW, Arsecularatne SN, Mendoza L. Phylogenetic analysis of *Rhinosporidium seeberi*'s 18S smallsubunit ribosomal DNA groups this pathogen among the members of the protactistan Mesomycetozoa clade. *J Clin Microbiol*. 1999;37:2750–2754.
- Fredericks DN, Jolley JA, Lepp PW, Kosek JC, Relman DA. *Rhinosporidium seeberi*: A human pathogen from a novel group of aquatic protistan parasites. *Emerg Infect Dis*. 2000;6:273–282.
- Ahluwalia KB, Maheshwari N, Deka RC. Rhinosporidiosis: A study that resolves etiologic controversies. *Am J Rhinol*. 1997;11:479–483.
- Nayak S, Rout TK, Acharjya B, Patra MK. Subcutaneous rhinosporidiosis. *Indian J Dermatol*. 2008;53:41–43.
- Jain S. Aetiology and incidence of rhinosporidiosis. *Indian J Otorhinol*. 1967;19:1–21.
- Goihman-Yahr M. Rhinoscleroma and rhinosporidiosis: an approach through history. *Int J Dermatol*. 1986;25:476–478.
- Kumari R, Laxmisha C, Thappa DM. Disseminated cutaneous rhinosporidiosis. *Dermatol Online J*. 2005;11:19.
- Padmavathy L, Rao IL, Sevam SS, Sahoo CG. Disseminated cutaneous rhinosporidiosis in a HIV seropositive patient. *Indian J Dermatol Venerol Leprol*. 2001;67:332–333.
- Arsecularatne SN. Recent advances in rhinosporidiosis and *Rhinosporidium seeberi*. *Indian J Med Microbiol*. 2002;20:119–131.
- Sinha A, Phukan JP, Bandyopadhyay G, et al. Clinicopathological study of rhinosporidiosis with special reference to cytodiagnosis. *J Cytol*. 2012;29:246–249.
- Arsecularatne SN. Chemotherapy of rhinosporidiosis: A review. *J Infect Dis Antimicrob Agents*. 2009; 26:21–27.
- Crosara PFTB, Becker CG, Freitas VA, Nunes FB, Becker HMG, Guimaraes RES. Nasal rhinosporidiosis: differential diagnosis of fungal sinusitis and inverted papilloma. *Intl. Arch. Otorhinolaryngol*. 2009;13:93–95.
- Nair KK. Clinical trial of diaminodiphenylsulfone (DDS) in nasal and nasopharyngeal rhinosporidiosis. *Laryngoscope*. 1979;89:291–295.

If you love learning and

# DERMATOLOGY

we've got the perfect meeting for you!

As an accredited leader in continuing education for over 11 years, we invite you to join us at one of our upcoming conferences.

All meetings are designed to provide cutting edge dermatology-focused curriculum combining a great blend of science and clinical medicine taught by our world-class faculty.

Designed specifically for Dermatologists

**Maui+Derm**  
FOR DERMATOLOGISTS

**JANUARY 28-FEBRUARY 1, 2018**  
Grand Wailea • Maui, Hawaii

Exclusively for Dermatology  
Nurse Practitioners & Physician Assistants

**MauiDerm**  
NP+PA **Summer**

**JUNE 21-23, 2018**  
Broadmoor Hotel • Colorado Springs, CO  
Plus Special Pre-Conference Day on  
June 20, 2018

**MauiDerm**  
NP+PA **Fall**

**SEPTEMBER 27-29, 2018**  
Riverside Hilton • New Orleans, LA  
Plus Special Pre-Conference Day on  
September 26, 2018

Visit our website for more information,  
meeting registration, hotel reservations and  
transportation arrangements.

IT'S SIMPLE, SAFE & SECURE.

REGISTER  
**EARLY**  
AND SAVE!

**skin**<sup>med</sup>  
DERMATOLOGY FOR THE CLINICIAN  
MEDIA PARTNER

[MauiDerm.com](http://MauiDerm.com)



## CASE STUDY

# Woodworm Bites in a 52-Year-Old Man

Claudio Conforti, MD;<sup>1,2</sup> Maria Silvestre, MD;<sup>1</sup> Caterina Dianzani, MD, PhD<sup>1</sup>

A 52-year-old man was admitted for clinical counseling at the Campus Bio-Medico in Rome in the early days of August 2017. He presented with multiple erythematohemorrhagic papules localized on the abdomen (Figure 1), back, arms, and thighs (Figure 2). The wide eruption was characterized by an intense reddish color that disappeared with diascopy. The patient stated that the eruption had appeared overnight after helping his mother-in-law dispose of a piece of antique furniture from her country villa the previous afternoon. Unexpectedly for the patient, the eruption did not cause intense itching during the night (it became more severe upon waking the next morning), and it did not affect his wife. (*SKINmed*. 2018;16:67–68)

The clinical presentation was extremely clear: the saliva of *Scleroderma*, with its anticoagulant and anesthetic properties, had created the typical bleeding pattern on the body of our patient. The differential diagnosis was very difficult. We excluded an infection caused by *Pyemotes herfsi*, in which lesions are generally smaller and less symptomatic.<sup>1</sup> In the differential diagnosis, we also included scabies and bedbug bites.

The patient was not febrile, even though he complained general malaise and asthenia. The lymph nodes were neither swollen nor painful. Blood tests were normal except for an increase in the range of neutrophils and eosinophils. Antinuclear antibodies and viral serology were negative. Histopathologic examination of a skin sample showed the presence of edema in the dermis, and perivascular infiltration of neutrophils with the occasional presence of some eosinophils.

We treated the patient with antihistamines and topical corticosteroids, and there was a marked improvement by day 4.

## DISCUSSION

*Scleroderma domesticum* is an insect belonging to the order Hymenoptera, family Betilidi. This insect has a slender body and is approximately 3 to 4 mm in length (Figure 3), not so different from the body of an ant. Its larvae are the common woodworm seen in furniture, where it also matures. *Scleroderma domesticum* attacks and feeds on the larvae of *Anobium punctatum*, *Hylotrupes bajulus*, *Lasioderma serricornis*, *Nicobium castaneum*, and *Stegobium paniceum*.<sup>2</sup> In absence of the usual prey, females of *S. domesticum* can

bite humans, usually several times, on the limbs, chest, and back. The maximum incidence of activity is from April to June, especially in countries with a temperate climate.<sup>3</sup>

Despite having a worldwide distribution, *S. domesticum* is more prevalent in temperate zones.<sup>4</sup> This may explain its spread in areas of Europe such as Italy and Spain. Numerous cases of *S. domesticum* bites have been reported in patients aged between 20 and 70 years in Italy. Both sexes were affected. A very small percentage of cases was related to *Scleroderma brevicornis*.<sup>3</sup>

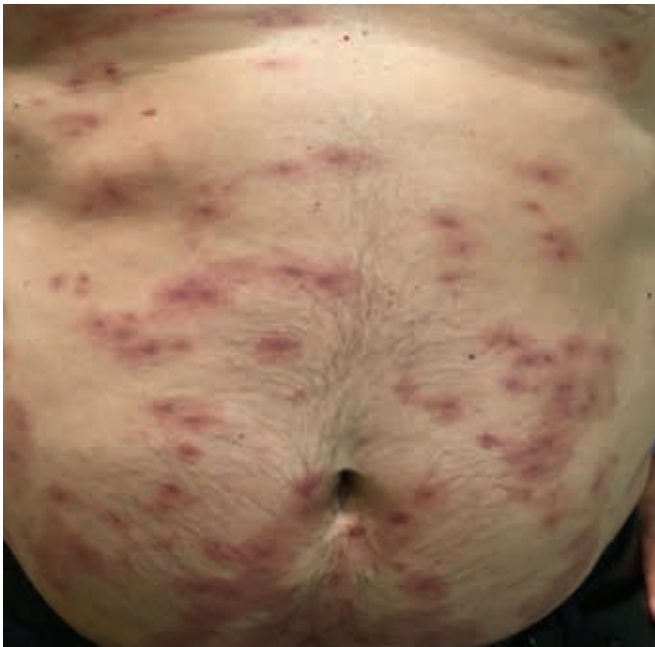Because the natural habitat of *S. domesticum* is represented by wooden objects, such as chairs, tables, and antique furniture, those most at risk of infestation by *Scleroderma* are restorers and antiquarians; for this reason, *Scleroderma* infestation is considered to be linked to professional environments.

The clinical response of a person stung by *S. domesticum* can vary from small local reactions to larger local reactions that may involve late-phase responses from IgE-mediated sensitivity.<sup>5,6</sup> *Scleroderma domesticum* belongs to the order Hymenoptera, and this explains why its stings can cause disseminated eruptions. In our patient, the clinical presentation was extremely clear: erythematous maculae, papules, and severe itching. Other dermatozoonoses can be evaluated in the differential diagnosis, for example stings caused by mites, but this diagnosis was excluded because the patient did not present the classic nocturnal itching and pathognomonic lesions of scabies.

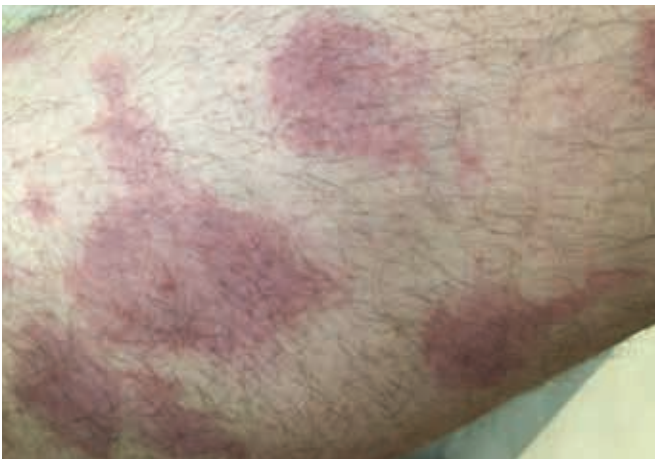Clinical manifestations disappeared after 4 days of topical treatments with corticosteroids and oral antihistamines.

From the Dermatology Unit, Campus Bio-Medico University, Rome, Italy;<sup>1</sup> and Non Melanoma Skin Cancer & Orphan Unit, Medical University of Graz, Graz, Austria<sup>2</sup>

Address for Correspondence: Claudio Conforti, MD, Dermatology Unit, Università Campus Biomedico, Via Alvaro del Portillo 200, 00128 Rome, Italy • E-mail: claudioconforti@yahoo.com, claudio.conforti@alcampus.it



**Figure 1.** Erythematous maculae and papules on the abdomen.



**Figure 2.** Erythematous maculae on the leg.



**Figure 3.** *Scleroderma domesticum*, belonging to the order Hymenoptera.

tinguish this kind of reaction from allergic reactions.<sup>3</sup> These elements must be taken into consideration to achieve an early diagnosis, which will lead to reduced clinical manifestations and an improved quality of life for the patient.

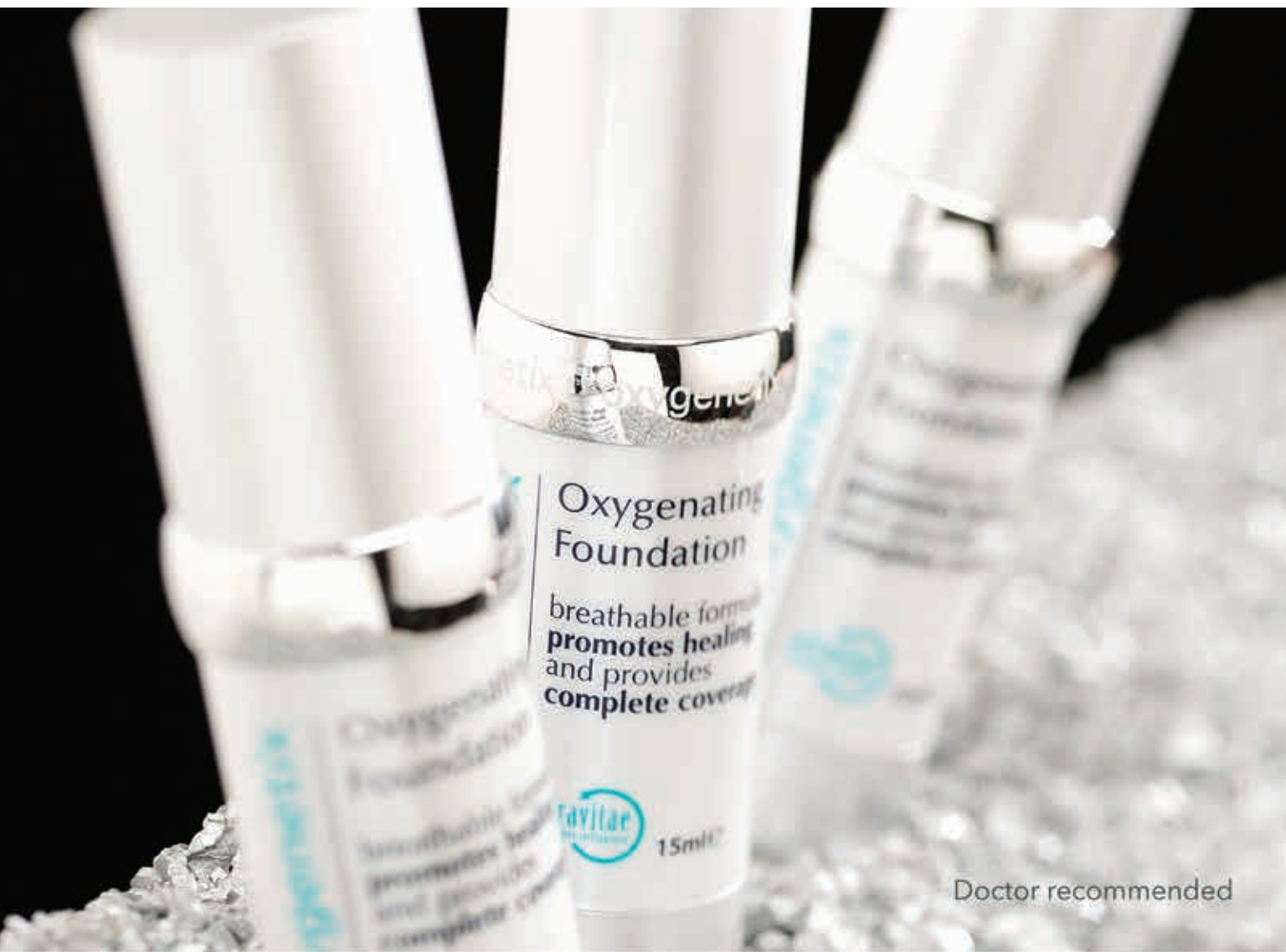## REFERENCES

- 1 Serini SM, Alberti Violetti S, Ferrucci SM, Süß L, Veraldi S. Sclerodermus domesticus infestation. *G Ital Dermatol Venereol.* 2010;145:713–715.
- 2 Lembo S, Panariello L, d'Errico FP, Lembo G. Professional's and non-professional's papular urticaria caused by *Scleroderma domesticum*. *Contact Dermatitis.* 2008;58:58–59.
- 3 Papini RA. A case of stings in humans caused by *Scleroderma* sp. in Italy. *J Venom Anim Toxins Incl Trop Dis.* 2014;20:11.
- 4 Ellis AK, Day JH. Clinical reactivity to insect stings. *Curr Opin Allergy Clin Immunol.* 2005;5:349–354.
- 5 Biló BM, Rueff F, Mosbech H, Bonifazi F, Oude-Elberink JNG. Diagnosis of hymenoptera venom allergy. *Allergy* 2005; 60:1339–1349.
- 6 Veraldi S, Maria Serini S, Violetti SA. Sclerodermus domesticus infestation: An occupational disease in antiquarians and restorers. *Dermatitis.* 2010;21:221–222.
- 7 Viglizzo G, Parodi A, Rebora A. Guess what! Multiple erythematohemorrhagic papules on the legs: Papular dermatitis induced by *Scleroderma domesticum*. *Eur J Dermatol.* 2002;12:207–208.

## CONCLUSIONS

Considering the sting of *S. domesticum* as a possible diagnosis is important because timely treatment allows complete remission within a few days of clinical manifestations that typically result in loss of working days if left untreated. *Scleroderma domesticum* infestation occurs mainly in carpenters, antiquarians, and restorers; for this reason, it can be considered an occupational disease.<sup>7</sup> A higher risk for reactions to Hymenoptera venom is reported in men.<sup>3</sup>

In the evaluation of the patient's response to insect stings, it is necessary to define whether reactions are local or systemic, to dis-



Doctor recommended

# oxygenetix

without Oxygenetix



with Oxygenetix



CO<sub>2</sub> fractional laser 1 day post procedure patient attended a dinner party looking great


Oxygenetix is a light-weight and breathable foundation originally created for medical use, and is now used on movie sets and fashion runways around the world, offering a full-coverage foundation while providing a sheer, yet flawless look.

Oxygenetix is free of fragrance, artificial colors and preservatives, making it safe for all skin types, even those with sensitive skin, while promoting health and healing.

Oxygenetix is a long-lasting foundation that will not run or smudge, making it ideal to wear for a day at the gym or a night on the town with confidence knowing that your natural beauty will shine through.

[learn more at oxygenetix.com](http://oxygenetix.com)





# INTERNATIONAL ACADEMY OF COSMETIC DERMATOLOGY

**Membership** in the International Academy of Cosmetic Dermatology is open to physicians with an interest in cosmetic dermatology and to members of the pharmaceutical and cosmetic industry who share similar goals.

Membership in the IACD is only \$195.00 a year and includes:

- Clinics in Dermatology - 6 issues per year
- Journal of Cosmetic Dermatology - 4 issues per year
- SKINmed - 6 issues per year
- Special discounts on travel and surgical supplies
- Reduced registration fee at IACD events

Corporate memberships are available at the Benefactor, Diamond, Platinum, Gold, and Silver levels.

## Individual Membership Application

First Name \_\_\_\_\_

Last Name \_\_\_\_\_

Title:  MD  PhD  MD,PhD  MS

Specialty:  Dermatologist  Plastic Surgeon

Other \_\_\_\_\_

Other \_\_\_\_\_

Address \_\_\_\_\_

City \_\_\_\_\_

State \_\_\_\_\_

Zip Code \_\_\_\_\_

Country \_\_\_\_\_

Tel \_\_\_\_\_

Fax \_\_\_\_\_

E-mail \_\_\_\_\_

Annual dues are US\$195, payable by:  VISA  MASTERCARD  AMEX  Check

Card # \_\_\_\_\_ Expiration date \_\_\_\_\_ CCV \_\_\_\_\_

Name on card \_\_\_\_\_

Signature if by fax or mail \_\_\_\_\_ Date \_\_\_\_\_

Please forward your completed application for processing to:

Larry E. Millikan, MD, Secretary-General

Ms Anna Gjeci, Executive Secretary

1508 Creswood Road

Philadelphia, PA 19115, USA

Tel: 215-677-3060

Cell: 267-438-2543

Fax: 215-695-2254

E-mail: IACDworld@yahoo.com

Web: www.IACDworld.org

For further information,  
please visit our website

[www.IACDworld.org](http://www.IACDworld.org)

**skin**  
DERMATOLOGY FOR THE CLINICIAN

MEDIA PARTNER



## CASE STUDY

# Multiple Grouped Scalp Nodules in a Middle-Aged Man: A Rare Case of Angiolymphoid Hyperplasia with Eosinophilia

Lina Husienzad, BS;<sup>1</sup> Ben Friedman, MD;<sup>2</sup> Sherry X. Yang, MD;<sup>2</sup>  
 Amber Tran, MSN, CRNP;<sup>2</sup> Jason B. Lee, MD<sup>2</sup>

An otherwise healthy man in his 50s presented complaining of pruritic lesions on the left side of his scalp. The lesions had slowly been growing in size over the preceding 30 years. They would occasionally bleed, and this is what ultimately prompted him to seek medical advice. Physical examination revealed multiple aggregated and soft, flesh-colored nodules on the left posterior auricular area of the scalp (Figure 1). No appreciable clinical lymphadenopathy was identified on examination. A shave biopsy of one of the nodules was performed for diagnostic clarification. (*SKINmed*. 2018;16:71–72)

**H**istopathologic examination revealed a patchy, nodular proliferation of vascular structures of varying thickness (Figure 2). Many of the vessels demonstrated prominent hobnail endothelial cells. A diffuse and polymorphous interstitial inflammatory infiltrate consisting of lymphocytes, plasma cells, and eosinophils was also observed. Given these findings, the patient was diagnosed with angiolymphoid hyperplasia with eosinophilia (ALHE). The patient was interested in treatment, and he was referred for surgical excision.

## DISCUSSION

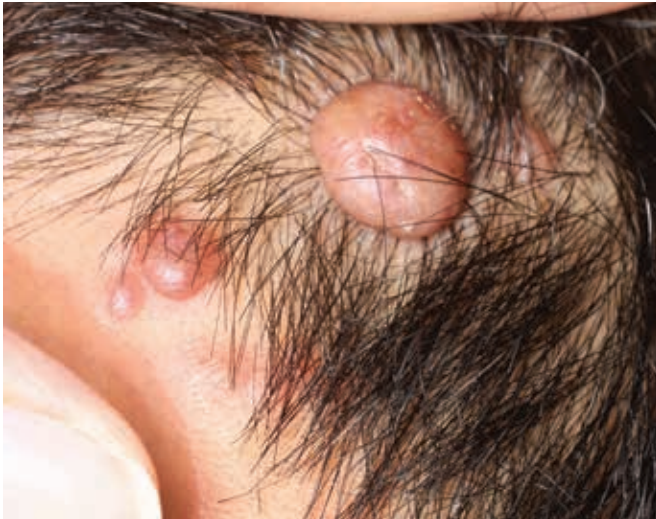ALHE is a rare vasoproliferative tumor, characterized by a proliferation of blood vessels in the dermis and subcutaneous tissue.<sup>1</sup> ALHE has a predilection for the skin and subcutaneous tissue of the head and neck; however, it has also been reported to occur at other sites, including the trunk, extremities, penis, and even visceral organs such as the colon.<sup>2</sup> It has a reported mean age of onset of approximately 30 years, although it may present between the ages of 20 and 50.<sup>3</sup> It is most commonly encountered in Asian populations, and has a slight female predominance.<sup>3</sup>

Patients with ALHE clinically present with a single or multiple aggregated flesh-colored-to-purple papules or nodules, which may be painful or pruritic.<sup>3</sup> There is often associated pulsation and spontaneous bleeding, due to the prominent vascularity of the lesions.<sup>3</sup> The characteristic histopathologic findings in ALHE are a proliferation of vascular structures with prominent hobnail endothelial cells among a dense background inflammatory infiltrate containing eosinophils and lymphocytes.<sup>4</sup> The pathophysiology underlying ALHE is poorly understood. Some have suggested that it may be a reactive process to trauma or infection, whereas many now classify it as an arteriovenous malformation or other vasoproliferative disorder.<sup>4</sup> Although it is considered to be a benign entity, it may persist and prove difficult to resolve even with treatment.<sup>3</sup>

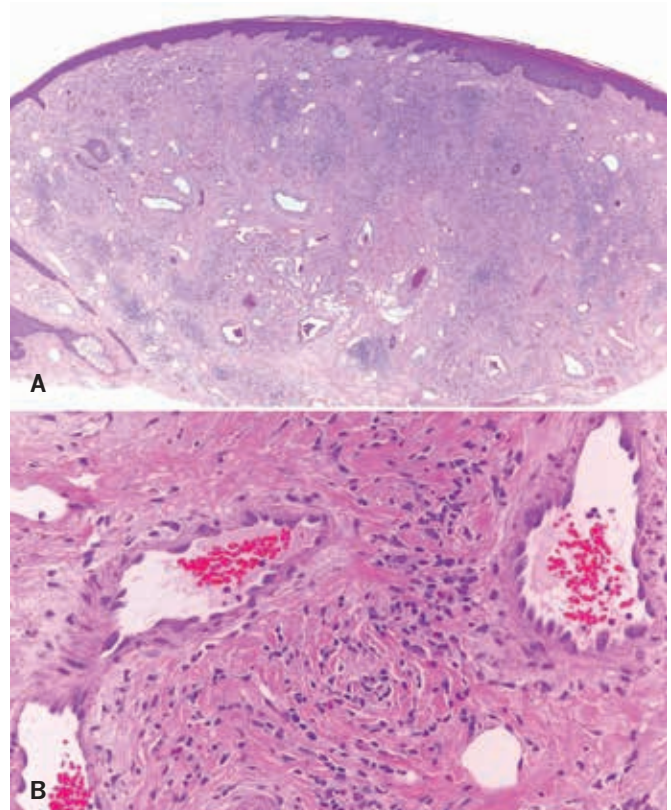
Clinically, ALHE can resemble Kimura disease, and both were previously thought to represent the same disease entity at different ends of a spectrum; however, there is some evidence to suggest that they are actually clinically and pathologically distinct.<sup>5</sup> Kimura disease often presents as a systemic illness and consists of a large subcutaneous mass in the head and neck region with

From Drexel University College of Medicine,<sup>1</sup> and the Department of Dermatology and Cutaneous Biology, Sidney Kimmel Medical College at Thomas Jefferson University,<sup>2</sup> Philadelphia, PA

Address for Correspondence: Ben Friedman, MD, Department of Dermatology, Henry Ford Health System, 3031 West Grand Blvd, Suite 800, Detroit, MI 48202 • E-mail: Bfriedm1@hfhs.org



**Figure 1.** Clinical image showing multiple grouped, flesh-pink-colored nodules on the left postauricular region of the scalp.



**Figure 2.** Histopathologic images of the excised lesions. (A) Dome-shaped nodule demonstrating a proliferation of thin- and thick-walled vessels along with a patchy interstitial inflammatory infiltrate (hematoxylin and eosin stain, original magnification  $\times 25$ ). (B) Dilated vascular structures lined by hobnail endothelial cells with a mixed surrounding inflammatory infiltrate consisting of lymphocytes, plasma cells, and prominent eosinophils (hematoxylin and eosin stain, original magnification  $\times 200$ ).

associated lymphadenopathy, eosinophilia, elevated immunoglobulin E levels, and renal disease.<sup>5</sup> Taken together, these features suggest that Kimura disease may represent a chronic, allergic inflammatory process.<sup>5</sup> Our patient lacked any signs of systemic disease, which made ALHE the more likely diagnosis in his case. Other entities that can resemble ALHE clinically include angiosarcoma, epithelioid hemangioendothelioma, Kaposi sarcoma, and pyogenic granuloma.<sup>6</sup> These entities can easily be distinguished on histology.<sup>6</sup>

Standard surgical excision is considered the most effective treatment to date for ALHE, although disease may recur in up to one-third of patients.<sup>7</sup> The high recurrence rate may reflect the difficulty of identifying the margins of this highly vascular lesion. Pulsed-dye laser, carbon dioxide laser, Mohs micrographic surgery, and topical immunomodulators are other modalities that have shown variable success in treating ALHE.<sup>7–10</sup> Cosmetic outcomes vary depending on the size and extent of the lesions.<sup>10</sup>

## REFERENCES

- 1 Wells GC, Whimster IW. Subcutaneous angiolymphoid hyperplasia with eosinophilia. *Br J Dermatol.* 1969;81:1–14.
- 2 Dewan P, Francis ND, Lear JT, Bunker CB. Angiolymphoid hyperplasia with eosinophilia affecting the penis. *Br J Dermatol.* 2008;159:755–757.
- 3 Adler BL, Krausz AE, Minuti A, Silverberg JI, Lev-Tov H. Epidemiology and treatment of angiolymphoid hyperplasia with eosinophilia (ALHE): A systematic review. *J Am Acad Dermatol.* 2016;74:506–512e11.
- 4 Olsen TG, Helwig EB. Angiolymphoid hyperplasia with eosinophilia: A clinicopathologic study of 116 patients. *J Am Acad Dermatol.* 1985;12(5 Pt 1):781–796.
- 5 Rajpoot DK, Pahl M, Clark J. Nephrotic syndrome associated with Kimura disease. *Pediatr Nephrol.* 2000;14:486–488.
- 6 Chun SI, Ji HG. Kimura's disease and angiolymphoid hyperplasia with eosinophilia: Clinical and histopathologic differences. *J Am Acad Dermatol.* 1992;27:954–958.
- 7 Adler BL, Krausz AE, Minuti A, Silverberg JI, Lev-Tov H. Epidemiology and treatment of angiolymphoid hyperplasia with eosinophilia (ALHE): A systematic review. *J Am Acad Dermatol.* 2016. 74:506–512.
- 8 Abrahamson TG, Davis DA. Angiolymphoid hyperplasia with eosinophilia responsive to pulsed dye laser. *J Am Acad Dermatol.* 2003;49(2 suppl case reports):S195–S196.
- 9 Redondo P, Del Olmo J, Idoate M. Angiolymphoid hyperplasia with eosinophilia successfully treated with imiquimod. *Br J Dermatol.* 2004;151:1110–1111.
- 10 Miller CJ, Ioffreda MD, Ammirati CT. Mohs micrographic surgery for angiolymphoid hyperplasia with eosinophilia. *Dermatol Surg.* 2004;30:1169–1173.

**The 2017 Recipient of the AAD Sulzberger  
Dermatologic Institute and Education  
Grants Committee's Program for Innovative  
Continuing Medical Education in  
Dermatology (PICMED) Grant**



- Stay current with the dermatology literature
- Featuring commentaries by Warren R. Heymann, MD (Professor of Medicine and Pediatrics, and Head, Division of Dermatology, Cooper Medical School of Rowan University; Clinical Professor of Dermatology, Perelman School of Medicine at the University of Pennsylvania)
- Earn free CME credit sponsored by The Cooper Health System

**Get your free subscription at  
[www.dermatologyinsightsandinquiries.com](http://www.dermatologyinsightsandinquiries.com)**

## CASE STUDY

# Glucose Monitoring Dermopathy

Warren R. Heymann, MD

A 75-year-old man had been monitoring his glucose using a blood glucose monitoring system at the same body site for at least 20 years (>7300 needlesticks). The asymptomatic skin lesion had been present for many years. He used the same site because it hurt less than the fingers and bled well. His medical history was remarkable for diabetes mellitus, hypertension, coronary artery disease, and a pacemaker. His medications included glipizide, metformin, carvedilol, furosemide, lisinopril, amlodipine, clopidogrel, and aspirin. Physical examination revealed a brown, slightly raised, rough plaque with focal, punctate hemorrhagic crusts, on the distal area of the right thigh (Figure 1). The clinical differential diagnosis was more likely to be lichen simplex chronicus than pigmented Bowen's disease. A skin biopsy demonstrated an acanthotic epidermis with coarse collagen bundles in a thickened papillary dermis with extravasated erythrocytes, consistent with a dermal reparative reaction (Figure 2). (*SKINmed*. 2017;15:74–75)

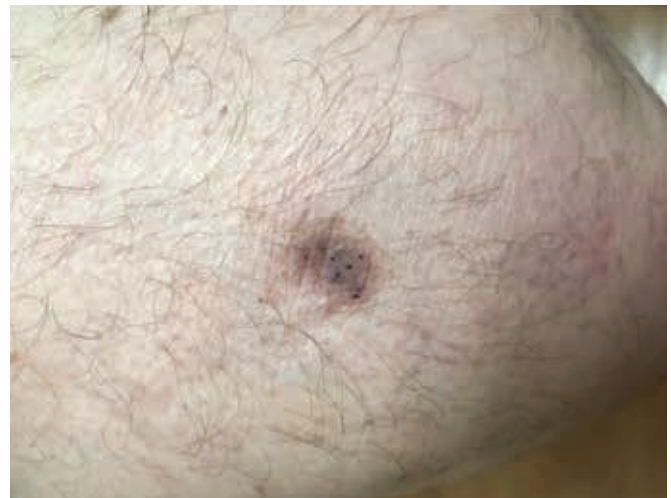Cutaneous manifestations of diabetes mellitus are well known to dermatologists and include necrobiosis lipoidica, diabetic dermopathy, diabetic bullae, scleroderma diabetorum, acanthosis nigricans, generalized granuloma annulare, eruptive xanthomatosis, and acquired perforating disorders.<sup>1</sup> Glucose monitoring is essential in managing diabetes mellitus. A novel skin lesion secondary to repeated needlestick monitoring is reported.

## DISCUSSION

Needlestick glucose monitoring has allowed for improved control of diabetes mellitus. Complications include pain at the injection site or infections such as *Pseudomonas aeruginosa* or *Staphylococcus aureus*.<sup>2</sup> Hepatitis B and C may occur when needles are shared<sup>3,4</sup>—a practice that should never happen. Injecting the needlestick into the fingertip yields the most accurate reading of serum glucose, although other body sites may be used at times when the glucose is likely not to rise or fall precipitously.<sup>5</sup> Some manufacturers recommend rotating the site of testing.

## CONCLUSIONS

Repeated needlestick injections at a solitary site for glucose monitoring may result in a hyperpigmented purpuric scar that could be mistaken for another neoplastic or inflammatory process. The purpuric

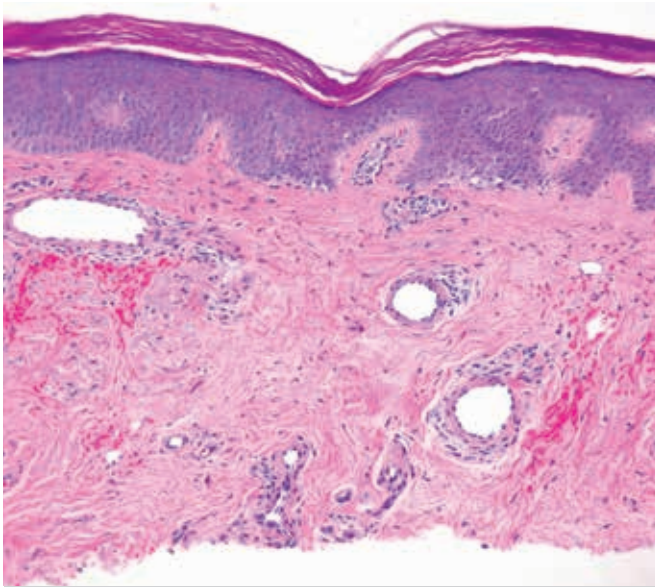


**Figure 1.** Glucose monitoring dermopathy presenting as a brown, slightly raised, rough plaque with focal, punctate hemorrhagic crusts, on the distal area of the right thigh.

component may be more prominent in patients who are anticoagulated. As there were no worrisome histologic features in our patient's case, in the context of a precise history, reassurance is all that is necessary. It may be prudent to advise rotating the site of needlestick injection to avoid this complication of glucose monitoring.

From the Division of Dermatology, Department of Medicine and Department of Pediatrics, Cooper Medical School of Rowan University, Marlton, NJ

Address for Correspondence: Warren R. Heymann, MD, Cooper Medical School of Rowan University, 100 Brick Road – Suite 306, Marlton, NJ 08053 • E-mail: wrheyman@gmail.com



**Figure 2.** The histology of glucose-monitoring dermatopathy, demonstrating an acanthotic epidermis with coarse collagen bundles in a thickened papillary dermis with extravasated erythrocytes, consistent with a dermal reparative reaction (hematoxylin and eosin stain, magnification  $\times 200$ ).

## ACKNOWLEDGMENT

Lawrence David Hall, MD, provided the histopathology photomicrograph.

## REFERENCES

- 1 Murphy-Chutorian B, Han G, Cohen SR. Dermatologic manifestations of diabetes mellitus: A review. *Endocrinol Metab Clin North Am.* 2013;42:869–898.
- 2 Jen S-P, Sharma R, Ravishankar J. Pseudomonas aeruginosa bacteremia secondary to fingerstick glucose monitoring. *J Infect.* 2010;60:382–385.
- 3 Desenclos JC, Bourdiol-Razès B, Rolin P, et al. Hepatitis C in a ward for cystic fibrosis and diabetic patients: Possible transmission by spring-loaded fingerstick devices for self-monitoring of capillary blood glucose. *Infect Control Hosp Epidemiol.* 2001;22:701–707.
- 4 Centers for Disease Control and Prevention. Transmission of hepatitis B virus among persons undergoing blood glucose monitoring in long-term care facilities – Mississippi, North Carolina, and Los Angeles County, California, 2003–2004. *MMWR Morb Mortal Wkly Rep.* 2005;54:220–223.
- 5 McCulloch DK. Patient education. Self-blood glucose monitoring in diabetes mellitus (Beyond the basics). UpToDate October 19, 2015.

## HISTORICAL DIAGNOSIS AND TREATMENT: EPITHELIOMA (Continued from page 53)

### SYPHILIS SECUNDARIA

#### Syphilis pustulosa.

The general pustular syphilid is of much less common occurrence than the papular, and is observed most often in poorly nourished, debilitated or anemic individuals, usually in the first three to eight months of the disease. Like the papular rash it may be the first recognized cutaneous manifestation; more often it follows or develops from a prior papular eruption. Pustules do not necessarily arise from papules, they may originate as pustules. When they appear in profusion their evolution is often preceded and accompanied by fever, headache and malaise. In the earlier rashes the pus is situated between the epidermis and the true skin. The later and relapsing forms are usually more limited in their distribution, the lesions are generally larger and the destruction deeper. In either case the pustules dry quickly with the formation of yellow, brown or greenish crusts which fall off and uncover characteristic ham colored papules with a collarette of shriveled epidermis at the periphery, or disclose shallow punched out ulcers which may leave permanent scars when they heal. The pustular rash has many characteristics in common with the papular, namely, the color, the general distribution, the moderate grouping of the lesions, the tendency for new lesions to appear for several days or weeks and for the efflorescences to be nearly all of one size, miliary, small or large. In the miliary pustular syphilid the le-

sions are usually profuse and situated about the hair follicles. A few large papules or pustules are nearly always present. The appearance of such an eruption is quite characteristic and not easily mistaken. Slightly larger pustules may resemble those of acne or variola. The rash causes no subjective symptoms except that in the negro itching is sometimes complained of. **DIAGNOSIS:** The pustular syphilid may simulate any of the pustular non-specific skin lesions. Of the very greatest importance in diagnosis is the presence of other symptoms of syphilis. Points to be considered in differentiating the pustular syphilid from acne are, that acne is very chronic and localized upon the face and upper trunk, it rarely arises after thirty, comedones are usually plentiful, and the nodes may be deep and are of a dusky and not a coppery red. *Variola* is distinguished by the sudden onset and intensity of its general symptoms, its acute course and definite duration, the shot-like feel of its papules and the full globular character of the pustules, the uniformity in character and development of the lesions and their predilection for the face, wrists and hands. In the exceedingly rare cases in which these points do not suffice for a differential diagnosis a serodiagnostic test will resolve all difficulties. **TREATMENT:** The general mercurial treatment is as a rule all that is required, though it is particularly in these cases that mercury vapor baths are serviceable.



# Cosmetic Surgery Forum



## REGISTER EARLY & SAVE!

### Discussions in Cosmetic Surgery & Dermatology

November 28 - December 1, 2018 at The Cosmopolitan of Las Vegas

[www.CosmeticSurgeryForum.com](http://www.CosmeticSurgeryForum.com)

### Practical. Honest. Insightful.

*"This is the best conference I've attended - quick, to the point, high-yield information - it's a great experience."*  
- Edward Nadimi, MD

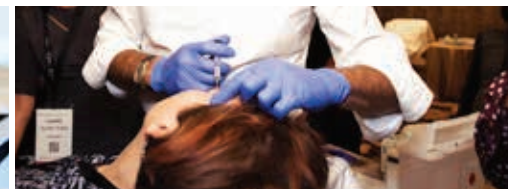*"The dynamic discussions are invaluable. And every session had an exorbitant amount of material to learn from."*  
- Jessica Feig, MD

*"This is my second year here and I'd have to say it's become my favorite meeting because of the great combination of science, education, straight talk and a lot of fun."*  
- Zakia Rahman, MD

*"Great talks and great discussion where people can really say how they feel and give real opinions. Really good information and a really good experience."*  
- Joely Kaufman, MD

*"I will continue to come back every year because it is honest and very fresh - this is one of the most honest meetings that there is."*  
- Jill Fitchel, MD

*"The conference started on Thursday morning at 8 o'clock and by 8:30 my life had changed. The very first talk was incredibly informative!"*  
- Candace Spann, MD



Course Director: Joel Schlessinger, MD \*CME credits are subject to change

For more information, please contact: Natasha Mohr • [info@CosmeticSurgeryForum.com](mailto:info@CosmeticSurgeryForum.com) • 402-697-6564

## CASE STUDY

# Bullosis Diabeticorum: A Neglected Bullous Dermatosi

Ramya Vangipuram, MD;<sup>1</sup> Tiffany Hinojosa, MD;<sup>2</sup> Daniel J. Lewis, BA;<sup>3,4</sup>  
 Christopher Downing, MD;<sup>5</sup> Caleb Hixson, DO;<sup>6</sup>  
 Julio César Salas-Alanis, MD, PhD;<sup>2</sup> Stephen K. Tyring, MD, PhD<sup>1,5</sup>

A 75-year-old African-American man presented with a 3-year history of painless, fluid-filled blisters, for which his primary care physician had treated him with doxycycline, cephalexin, and topical corticosteroids, with no significant improvement. The blisters had ruptured spontaneously and healed with scarring. He denied antecedent trauma. His medical history was remarkable for insulin-dependent type 2 diabetes mellitus, hypertension, hypercholesterolemia, primary cutaneous melanoma status-post excision, and breast cancer status-post mastectomy and chemotherapy. Physical examination revealed nontender bullae, measuring up to 4 cm × 3 cm and containing serous fluid, on the anterior portion of both tibias (Figure 1). The Nikolsky sign was negative. There was no evidence of surrounding inflammation. A biopsy revealed subepidermal bullae formation with sparse inflammatory infiltrate (Figure 2). Direct and indirect immunofluorescence studies were negative for immunoglobulin (Ig) G, IgA, IgM, complement C3, C5b-9, and fibrinogen deposition. Culture of the bullous fluid was negative. (*SKINmed*. 2018;16:77–79)

Given these negative findings, the patient was diagnosed with bullous dermatosis (BD) and given topical mupirocin cream to prevent infection after the bullae ruptured. After 1 month, his condition had not changed.

## DISCUSSION

BD is a rare, underreported cutaneous manifestation of diabetes mellitus.<sup>1,2</sup> The disease is characterized by the spontaneous appearance of flaccid or tense bullae located on acral sites, often draining serous fluid.<sup>3</sup> It is a relapsing and remitting disease. The bullae classically heal without scarring; our patient had an atypical presentation including healing with scarring. The microscopic location of the intercellular split varies and can occur in an intraepidermal or subepidermal manner.<sup>4</sup> The pathogenesis of BD remains uncertain but may involve a response to trauma on acral locations as a complication of diabetic neuropathy and microangiopathy.<sup>2,3</sup>

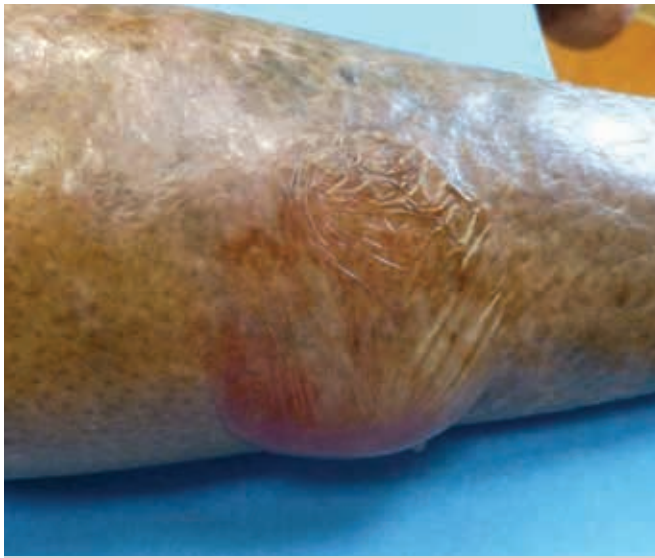
Treatment of BD is typically supportive.<sup>1–4</sup> The bullae should be kept intact to prevent secondary infection. Topical therapy is generally not required, although topical antibiotics such as mupirocin may prevent infection. In cases of tissue necrosis, debridement and tissue grafting should be considered.<sup>1</sup> Reports of osteomyelitis and infection requiring amputation arising at the site of bullous disease illustrate the importance of monitoring for secondary infection and providing aggressive wound healing intervention, as with diabetic ulcers, if the bullae become unroofed.<sup>2</sup>

## CONCLUSIONS

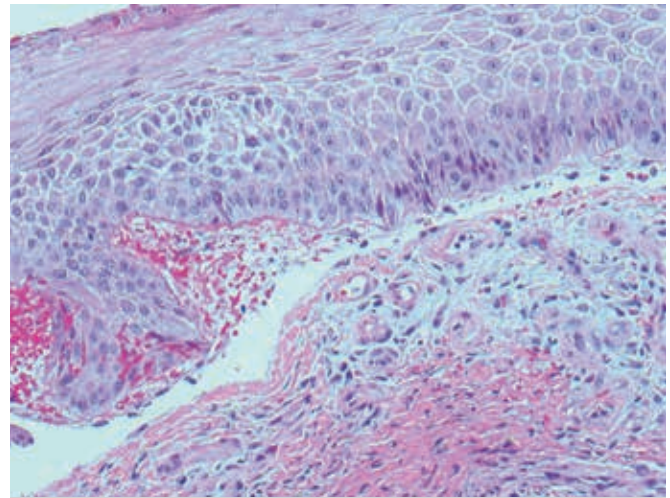
The clinical features of BD are nonspecific. The bullae seen in bullous pemphigoid, epidermolysis bullosa acquisita, and porphyria cutanea tarda may mimic those of BD (Table). Microscopy and direct and indirect immunofluorescence features are used to exclude these diseases. In our case, the biopsy findings were consistent with diabetic bullae and supported by the history of diabetes. BD is a

From the Center for Clinical Studies, Houston, TX;<sup>1</sup> the Division de Ciencias de la Salud, Universidad de Monterrey, San Pedro, Garza García, Nuevo León, Mexico;<sup>2</sup> the School of Medicine, Baylor College of Medicine, Houston, TX;<sup>3</sup> the Department of Dermatology, The University of Texas MD Anderson Cancer Center, Houston, TX;<sup>4</sup> the Department of Dermatology,<sup>5</sup> and the Department of Dermatopathology,<sup>6</sup> University of Texas Health Science Center at Houston, Houston, TX

Address for Correspondence: Ramya Vangipuram, MD, Center for Clinical Studies, 451 North Texas Avenue, Webster, TX 77598 • E-mail: rvangip@gmail.com



**Figure 1.** Tense, fluid-filled bulla on the lower extremity.



**Figure 2.** Biopsy showing subepidermal bulla formation and sparse inflammatory infiltrate (hematoxylin and eosin stain, original magnification ×20).

**Table. Differential Diagnosis of Bullous Diabeticorum**

DERMATOSIS	HISTOLOGY FINDINGS	DIF	IDIF	CLINICAL FEATURES
Pemphigus vulgaris <sup>5</sup>	Intraepidermal bullae, eosinophils, loss of intercellular attachments in basement membrane	Reticular pattern of IgG and complement deposits around epidermal cells	IgG binds to desmoglein	Presents in skin and oral mucosa; positive Nikolsky sign; flaccid bullae that rupture easily leaving shallow erosions
Bullous pemphigoid <sup>5</sup>	Subepidermal bullae, eosinophil-predominant inflammatory infiltrate	Linear-pattern (N-serrated) of IgG and complement C3 deposition at epidermal-dermal junction	IgG binds to hemidesmosomes and upper lamina lucida	Presents only in skin; negative Nikolsky sign; tense bullae that do not rupture easily
Dermatitis herpetiformis <sup>6</sup>	Subepidermal bullae, neutrophilic microabscesses	Granular pattern of IgA deposits in upper papillary dermis		Pruritic, grouped vesicles and bullae
Epidermolysis bullosa acquisita <sup>7</sup>	Subepidermal bullae, mixed inflammatory cell infiltrate	Linear pattern (U-serrated) of IgG, IgM or IgA, and C3 deposition at basement membrane	IgG binds to dermal floor	Mild mucosal involvement; healing with dense scars at trauma areas
Porphyria cutanea tarda <sup>8</sup>	Free-cell subepidermal bullae, festooning of the dermal papillae	Granular pattern of IgG, and C3 deposition at the basement membrane zone and dermal capillaries	—	Sunlight exposure with subsequent appearance of lesions; additional hair growth and pigmentation changes
Drug-induced linear IgA <sup>9</sup>	Subepidermal bullae, neutrophilic microabscesses	Linear pattern of IgA at basement membrane	IgA binds to basement membrane	Transient pruritus or burning preceding lesions; commonly precipitated by sulfa drugs, β-lactams, and phenytoin
Bullous diabeticorum <sup>1-4</sup>	Intraepidermal or subepidermal bullae, sparse inflammatory infiltrate	Negative for IgG, IgA, IgM, C3, C5b-9, and fibrinogen deposition	Negative for IgG, IgA, IgM, C3, C5b-9, and fibrinogen deposition	Spontaneous appearance of tense or flaccid bullae on acral sites; often drain serous fluid; self-remitting

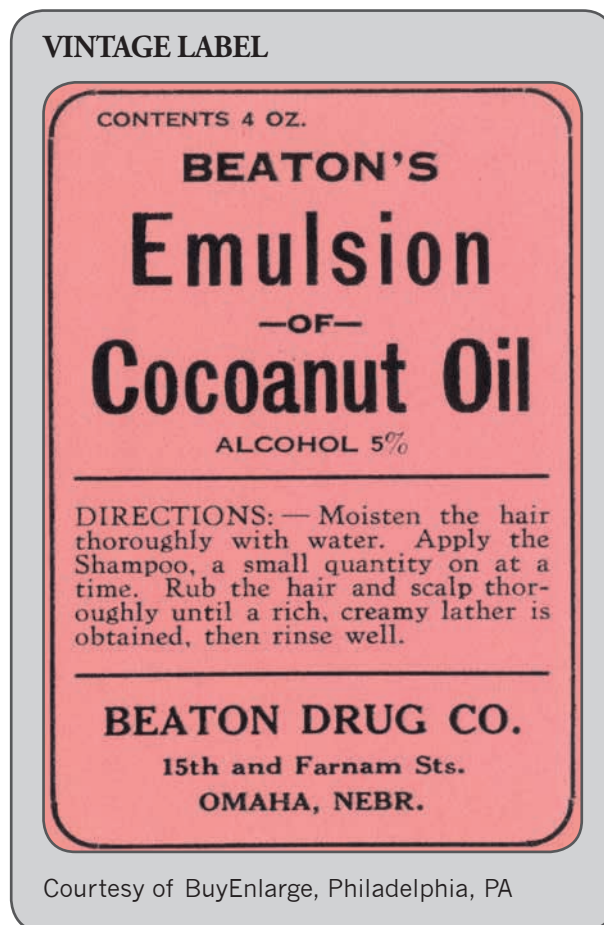
Abbreviations: C, complement; DIF, direct immunofluorescence; IDIF, indirect immunofluorescence; Ig, immunoglobulin.



diagnosis of exclusion. A detailed study to differentiate the histopathology of other BDs may help in understanding the evolution of this condition, resulting in improved management and prevention.

## REFERENCES

- 1 Lipsky BA, Baker PD, Ahroni JH. Diabetic bullae: 12 cases of a purportedly rare cutaneous disorder. *Int J Dermatol*. 2000;39:196–200.
- 2 Larsen K, Jensen T, Karlsmark T, Holstein PE. Incidence of bullosis diabeticorum—a controversial cause of chronic foot ulceration. *Int Wound J*. 2008;5:591–596.
- 3 Mota AN, Nery NS, Barcaui CB. Case for diagnosis: Bullosis diabeticorum. *An Bras Dermatol*. 2013;88:652–654.
- 4 Toonstra J. Bullosis diabeticorum. Report of a case with a review of the literature. *J Am Acad Dermatol*. 1985;13:799–805.
- 5 Kershenovich R, Hodak E, Mimouni D. Diagnosis and classification of pemphigus and bullous pemphigoid. *Autoimmun Rev*. 2014;13:477–481.
- 6 Caproni M, Antiga E, Melani L, Fabbri P, Italian Group for Cutaneous I. Guidelines for the diagnosis and treatment of dermatitis herpetiformis. *J Eur Acad Dermatol Venereol*. 2009;23:633–638.
- 7 Kim JH, Kim SC. Epidermolysis bullosa acquisita. *J Eur Acad Dermatol Venereol*. 2013;27:1204–1213.
- 8 Schulenburg-Brand D, Katugampola R, Anstey AV, Badminton MN. The cutaneous porphyrias. *Dermatol Clin*. 2014;32:369–384, ix.
- 9 Fortuna G, Salas-Alanis JC, Guidetti E, Marinkovich MP. A critical reappraisal of the current data on drug-induced linear immunoglobulin A bullous dermatosis: A real and separate nosological entity? *J Am Acad Dermatol*. 2012;66:988–994.



**DerMend® Mature Skin Solutions** offers products designed with dermatologists specifically for the unique skin conditions mature patients experience.

The DerMend line of products contains unique formulas to help restore, rejuvenate and maintain skin health and a more youthful appearance for mature patients.

### Improve the Appearance of Bruised Skin

DerMend Moisturizing Bruise Formula offers targeted care to improve the appearance of bruised skin while rejuvenating and helping restore the skin's natural barrier with:

- Retinol
- Ceramides
- Vitamin K
- Glycolic acid
- Arnica oil
- Niacinamide

### Fast, Effective Itch Relief

DerMend Moisturizing Anti-Itch Lotion offers targeted, gentle care to relieve dry, itchy and irritated skin without steroids. The exclusive formula restores much-needed moisture to mature skin and the pramoxine HCl safely stops itch quickly and effectively.

- Relieves itch quickly with pramoxine HCl
- Helps improve skin texture with moisturizers and skin conditioning agents
- Steroid-free

### Rejuvenate Thin, Fragile Skin

The unique combination of ingredients in DerMend Fragile Skin Moisturizing Formula can help rejuvenate thin, fragile skin, giving it a more youthful appearance.

- Hyaluronic acid
- Glycolic acid
- Retinol
- Niacinamide
- A unique combination of ceramides

Visit [DerMend.com](http://DerMend.com) or call (866) 668-7482 for more information.



## Healthy Skin at Any Age

**Levulan® Kerastick® (aminolevulinic acid HCl) for Topical Solution, 20%**  
Initial U.S. approval: 1999

**INDICATIONS AND USAGE**

The LEVULAN KERASTICK for Topical Solution, a porphyrin precursor, plus blue light illumination using the BLU-U® Blue Light Photodynamic Therapy Illuminator is indicated for the treatment of minimally to moderately thick actinic keratoses of the face or scalp.

**CONTRAINDICATIONS**

The LEVULAN KERASTICK for Topical Solution plus blue light illumination using the BLU-U Blue Light Photodynamic Therapy Illuminator is contraindicated in patients with cutaneous photosensitivity at wavelengths of 400-450 nm, porphyria or known allergies to porphyrins, and in patients with known sensitivity to any of the components of the LEVULAN KERASTICK for Topical Solution.

**WARNINGS AND PRECAUTIONS**

**Photosensitivity**

During the time period between the application of LEVULAN KERASTICK Topical Solution and exposure to activating light from the BLU-U Blue Light Photodynamic Therapy Illuminator, the treatment site will become photosensitive. After LEVULAN KERASTICK Topical Solution application, patients should avoid exposure of the photosensitive treatment sites to sunlight or bright indoor light (e.g., examination lamps, operating room lamps, tanning beds, or lights at close proximity) during the period prior to blue light treatment. Exposure may result in a stinging and/or burning sensation and may cause erythema and/or edema of the lesions. Before exposure to sunlight, patients should, therefore, protect treated lesions from the sun by wearing a wide-brimmed hat or similar head covering of light-opaque material. Sunscreens will not protect against photosensitivity reactions caused by visible light. It has not been determined if perspiration can spread the LEVULAN KERASTICK Topical Solution outside the treatment site to eye or surrounding skin.

Application of LEVULAN KERASTICK Topical Solution to perilesional areas of photodamaged skin of the face or scalp may result in photosensitization. Upon exposure to activating light from the BLU-U Blue Light Photodynamic Therapy Illuminator, such photosensitized skin may produce a stinging and/or burning sensation and may become erythematous and/or edematous in a manner similar to that of actinic keratoses treated with LEVULAN KERASTICK Photodynamic Therapy. Because of the potential for skin to become photosensitized, the LEVULAN KERASTICK should be used by a qualified health professional to apply drug only to actinic keratoses and not perilesional skin. If for any reason the patient cannot return for blue light treatment during the prescribed period after application of LEVULAN KERASTICK Topical Solution (14 to 18 hours), the patient should call the doctor. The patient should also continue to avoid exposure of the photosensitized lesions to sunlight or prolonged or intense light for at least 40 hours. If stinging and/or burning is noted, exposure to light should be reduced.

**Irritation**

The LEVULAN KERASTICK Topical Solution contains alcohol and is intended for topical use only. Do not apply to the eyes or to mucous membranes. Excessive irritation may be experienced if this product is applied under occlusion.

**Coagulation Defects**

The LEVULAN KERASTICK for Topical Solution has not been tested on patients with inherited or acquired coagulation defects.

**ADVERSE REACTIONS**

In Phase 3 studies, no non-cutaneous adverse events were found to be consistently associated with LEVULAN KERASTICK Topical Solution application followed by blue light exposure.

**Photodynamic Therapy Response:** The constellation of transient local symptoms of stinging and/or burning, itching, erythema and edema as a result of LEVULAN KERASTICK Topical Solution plus BLU-U treatment was observed in all clinical studies of LEVULAN KERASTICK for Topical Solution Photodynamic Therapy for actinic

keratoses treatment. Stinging and/or burning subsided between 1 minute and 24 hours after the BLU-U Blue Light Photodynamic Therapy Illuminator was turned off, and appeared qualitatively similar to that perceived by patients with erythropoietic protoporphyria upon exposure to sunlight. There was no clear drug dose or light dose dependent change in the incidence or severity of stinging and/or burning.

In two Phase 3 trials, the sensation of stinging and/or burning appeared to reach a plateau at 6 minutes into the treatment. Severe stinging and/or burning at one or more lesions being treated was reported by at least 50% of the patients at some time during treatment. The majority of patients reported that all lesions treated exhibited at least slight stinging and/or burning. Less than 3% of patients discontinued light treatment due to stinging and/or burning.

In the Phase 3 trials, the most common changes in lesion appearance after LEVULAN KERASTICK for Topical Solution Photodynamic Therapy were erythema and edema. In 99% of active treatment patients, some or all lesions were erythematous shortly after treatment, while in 79% of vehicle treatment patients, some or all lesions were erythematous. In 35% of active treatment patients, some or all lesions were edematous, while no vehicle-treated patients had edematous lesions. Both erythema and edema resolved to baseline or improved by 4 weeks after therapy. LEVULAN KERASTICK Topical Solution application to photodamaged perilesional skin resulted in photosensitization of photodamaged skin and in a photodynamic response (see Warnings and Precautions).

**Other Localized Cutaneous Adverse Experiences:**

Table 1 depicts the incidence and severity of cutaneous adverse events in Phase 3 studies, stratified by anatomic site treated.

Degree of Severity	Active Treatment		Vehicle Treatment	
	Patients	%	Patients	%
Any CAE	100	100	100	100
Mild	95	95	95	95
Severe	5	5	5	5
Edema	35	35	0	0
Erythema	99	99	79	79
Stinging and/or burning	50	50	0	0
Itching	10	10	0	0
Prickling	10	10	0	0
Swelling	10	10	0	0
Redness	100	100	100	100
Warmth	100	100	100	100
Blurred vision	0	0	0	0
Headache	0	0	0	0
Nausea	0	0	0	0
Dizziness	0	0	0	0
Flushing	0	0	0	0
Diarrhea	0	0	0	0
Constipation	0	0	0	0
Abdominal pain	0	0	0	0
Back pain	0	0	0	0
Joint pain	0	0	0	0
Muscle pain	0	0	0	0
Rash	0	0	0	0
Skin discoloration	0	0	0	0
Unpleasant taste	0	0	0	0
Unpleasant smell	0	0	0	0
Unpleasant feeling	0	0	0	0
Unpleasant appearance	0	0	0	0
Unpleasant taste/smell/feeling/appearance	0	0	0	0

**Adverse Experiences Reported by Body System:**

In the Phase 3 studies, 7 patients experienced a serious adverse event. All were deemed remotely or not related to treatment. No clinically significant patterns of clinical laboratory changes were observed for standard serum chemical or hematologic parameters in any of the controlled clinical trials.

**OVERDOSAGE**

**LEVULAN KERASTICK Topical Solution Overdose**

LEVULAN KERASTICK Topical Solution overdose has not been reported. In the unlikely event that the drug is ingested, monitoring and supportive care are recommended. The patient should be advised to avoid incidental exposure to intense light sources for at least 40 hours after ingestion. The consequences of exceeding the recommended topical dosage are unknown.

**BLU-U Light Overdose**

There is no information on overdose of blue light from the BLU-U Blue Light Photodynamic Therapy Illuminator following LEVULAN KERASTICK Topical Solution application.

**Information for Patients:**

LEVULAN KERASTICK Photodynamic Therapy for Actinic Keratoses.

- The first step in LEVULAN KERASTICK Photodynamic Therapy (PDT) for actinic keratoses is application of the LEVULAN KERASTICK Topical Solution to actinic keratoses located on the patient's face or scalp.

- After LEVULAN KERASTICK Topical Solution is applied to the actinic keratoses in the doctor's office, the patient will be told to return the next day. During this time the actinic keratoses will become sensitive to light (photosensitive). Care should be taken to keep the treated actinic keratoses dry and out of bright light. After LEVULAN KERASTICK Topical Solution is applied, it is important for the patient to wear light-protective clothing, such as a wide-brimmed hat, when exposed to sunlight or sources of light.

- Fourteen to eighteen hours after application of LEVULAN KERASTICK Topical Solution the patient will return to the doctor's office to receive blue light treatment, which is the second and final step in the treatment. Prior to blue light treatment, the actinic keratoses will be rinsed with tap water. The patient will be given goggles to wear as eye protection during the blue light treatment.

- The blue light is of low intensity and will not heat the skin. However, during the light treatment, which lasts for approximately 17 minutes, the patient will experience sensations of tingling, stinging, prickling or burning of the treated lesions. These feelings of discomfort should improve at the end of the light treatment.

- Following treatment, the actinic keratoses and, to some degree, the surrounding skin, will redden, and swelling and scaling may also occur. However, these lesion changes are temporary and should completely resolve by 4 weeks after treatment.

LEVULAN, KERASTICK, BLU-U and DUSA are registered trademarks of DUSA Pharmaceuticals, Inc., a Sun Pharma company. Sun Dermatology is a division of Sun Pharmaceutical Industries, Inc.

© 2016 Sun Pharmaceutical Industries, Inc. All rights reserved.

US Patents: 5,954,703,

Manufactured for: DUSA Pharmaceuticals, Inc.®  
25 Upton Drive, Wilmington, MA 01887

For more information please contact: 1-877-533-3872 or 1-978-657-7500  
www.dusapharma.com

LAB-1442AW Rev D





**REDISCOVER**

**LEVULAN<sup>®</sup>**  
**KERASTICK<sup>®</sup>**

(aminolevulinic acid HCl)  
for Topical Solution, 20%

**+ BLU-U<sup>®</sup>**

Blue Light Photodynamic Therapy  
Illuminator Model 4170

**FOR MORE INFORMATION**  
**CONTACT US AT (877) 533-DUSA**

**Please see full prescribing information on adjacent page.**

LEVULAN, KERASTICK, BLU-U and DUSA are registered trademarks  
of DUSA Pharmaceuticals, Inc., a Sun Pharma company.  
©2016 DUSA Pharmaceuticals, Inc. All rights reserved.



**SUN**  
DERMATOLOGY

MKT-1790AW Rev C